Journal of Interventional Cardiac Electrophysiology 12, 115–122, 2005
© 2005 Springer Science + Business Media, Inc. Manufactured in The Netherlands.

Late Occurrence of Adenosine-Sensitive Focal Junctional Tachycardia in Complex Congenital Heart Disease

Eun-Jung Bae,[1] Chung-Il Noh,[1] Jung-Yun Choi,[1] Yong-Soo Yun,[1] Woong-Han Kim,[2] Jeong-Ryul Lee,[2] and Yong-Jin Kim[2]
Departments of [1]Pediatrics and [2]Thoracic Surgery, Seoul National University Children's Hospital, Seoul, South Korea

Abstract. Background: Although supraventricular tachycardia in complex congenital heart disease (CHD) has been reported after surgical repair, its exact electrophysiologic identification has been limited to intraatrial reentrant tachycardia (IART). Moreover, junctional tachycardia (JT) has not previously been described as a cause of late postoperative arrhythmia.

Methods and Results: Since 1993, a total of 12 patients with congenital heart disease presented with paroxysmal focal JT. The patients with only typical immediate postoperative junctional ectopic tachycardia were excluded. Medical records, standard electrocardiography and Holter monitoring were reviewed. An intracardiac electrophysiologic (EP) study was performed in 11 patients. Ten patients were in post-Fontan status (5.7% of total Fontan survivors). Focal JT occurred more frequently in heterotaxy syndrome among the Fontan survivors (7/52 vs. 3/124; $p < 0.05$). The commonest anatomy of the atrioventricular (AV) junction was complete AV canal in 8 patients. EP characteristics of focal JT were as follows: (1) various tachycardia mechanisms were identified (increased automaticity or a triggered mechanism in 6/11, and focal reentry in 5/11, including one concealed nodofascicular pathway) (2) ventriculoatrial conduction during tachycardia was either dissociation (7/12) or variable (5/12) (3) All JTs were terminated by adenosine. Class III antiarrhythmic agent was effective in 5/6. His bundle ablation was performed in one Fontan patient, who already had pacemaker because of accompanying intractable IART and sinus node dysfunction.

Conclusion: Focal JT may be a source of late term supraventricular tachycardia in patients with complex CHD. The tachycardia mechanism was either automatic/triggered or reentrant. In all patients, JT was effectively terminated by adenosine.

Key Words. focal junctional tachycardia, congenital heart disease, Fontan operation, heterotaxy syndrome, adenosine

Introduction

Because of recent surgical advances, many children with complex congenital heart disease survive after corrective or palliative repair. However, tachyarrhythmia is recognized to be an important source of early and late morbidity and mortality. Wolff–Parkinson–White syndrome, intraatrial reentrant tachycardia (IART), atrial fibrillation, and ventricular tachycardia have been reported in association with congenital heart defects [1]. Although several studies have reported that supraventricular tachycardia occurs frequently as a major cause of arrhythmia after Fontan repair, especially in heterotaxy syndrome, the exact electrophysiologic mechanisms have not been elucidated [1–4]. Atrioventricular (AV) reentrant tachycardia involving twin nodes may be one cause for supraventricular tachycardia [5–7]. Junctional ectopic tachycardia (JET) in congenital heart disease has only been described as a transient arrhythmia, which occurs immediately after surgical repair, usually within 3 days [8,9]. We studied 12 cases of paroxysmal focal junctional tachycardia with congenital heart disease and defined electrophysiologic characteristics.

Methods

A review of the medical records of all patients with focal junctional tachycardia and congenital heart disease was performed. Focal junctional tachycardia was defined in terms of the following electrocardiographic (ECG) and electrophysiologic (EP) characteristics: (1) rapid, often irregular, narrow QRS tachycardia with the same QRS morphology as in supraventricular (sinus or atrial) rhythm; (2) features of either ventriculoatrial (VA) dissociation or variable VA conduction; (3) in the case of a 1:1 VA relation, an atrium not actively involved in tachycardia maintenance; and (4) no signs of

Address for correspondence: Chung-Il Noh, MD, Department of Pediatrics, Seoul National University Children's Hospital, 28 Yongon-dong, Chongro-gu, Seoul, 110-744, South Korea. E-mail: chungnoh@plaza.snu.ac.kr

Received 10 August 2004; accepted 9 December 2004

typical AV reentrant or AV nodal reentrant tachycardia. The ECG features of focal JT were similar to those of JET. The tachycardia occurrence was grouped into 3 categories (immediate, early and late) according to the timing of its occurrence after operation: immediate postoperative tachycardia, within 7 days; early postoperative tachycardia, between 8 and 30 days; late postoperative tachycardia, after 30 days. One patient with preoperative Ebstein's anomaly showing incessant JET and two patients presenting typical persistent congenital JET in neonatal period with apparently normal heart were excluded. Adenosine was not tried for the incessant JT and it was unable to terminate the typical congenital JET.

We excluded the patients with typical JET occurred "only" during the immediate postoperative period, but included one patient with atypical immediate postoperative JET who had focal JT induction during follow-up electrophysiology study 6 years later. All 12-lead surface ECG and Holter monitoring data and EPS results were reviewed. A diagnosis of heterotaxy syndrome, such as right atrial isomerism or left atrial isomerism, was made according to previously reported criteria [6].

Values are reported as mean ± standard deviation. Univariate analysis of differences between the two groups was performed using the χ^2 test. A p value of <0.05 was considered significant.

Results

Since January 1993, 12 patients were identified as having paroxysmal focal junctional tachycardia. All patients had congenital heart disease. Eleven patients underwent EP study to confirm a tachycardia mechanism. Ten patients had complex heart anomaly with single ventricle physiology and all of the 10 had undergone Fontan type palliation (lateral tunnel operation in 7, an extracardiac conduit Fontan operation in 2, and an extracardiac lateral tunnel in 1). The other 2 patients had a corrected transposition of the great arteries (TGA) and repaired pulmonary atresia with intact ventricular septum, respectively. Clinical characteristics are summarized in Table 1. Heart rate during JT was relatively fast and the RR interval of JT was 306 ± 42 ms (240–400 ms). Four of the 12 patients had severe symptoms such as syncope or presyncope.

In total of 176 patients have been followed among Fontan survivors in our institution since 1988, and 10/176 (5.7%) had paroxysmal focal

Table 1. Clinical characteristics

Pt. no	Anomaly	Age (onset/EPS)	Surgery at EPS	Symptom	Early PO JET	Associated rhythm abn.	Antiarrhythmic Tx	Outcome
1	DIRV, DORV	4m/9y	Fontan op	Presyncope	+	IART SND	Sotalol, Pacemaker His bundle ablation	No Sx for 1 y after RFCA
2	RAI, CAVC, RV	4y/4y	Fontan op	Palpitation	+	–	Sotalol	No Sx for 2 y
3	RAI, DIRV	2y/12y	Fontan op	Presyncope	–	Twin AV node	Amiodarone for 3 y	No Sx without medication for 8y
4	LAI, CAVC, balanced V	19y/-	Fonatn op	Presyncope	+	Twin AV node	Amiodarone	No Sx for 6 m
5	CAVC, balanced V	9y/10y	Fontan op	Palpitation	+	–	Atenolol	No Sx for 1 y
6	Corrected TGA	8y/10y	–	Palpitation			Sotalol, Digoxin	Partial response
7	PA IVS	17y/19y	RVOT	Palpitation	?	PVC	Nadolol	No Sx for 2 y
8	RAI, CAVC, balanced V	14y/14y	Fontan op	Palpitation	+	–	–	No Sx after AVVR for 6 months
9	RAI, CAVC, RV	1y/13y	Fontan op	Syncope	+	Twin AV node	Nadolol	Partial response
10	RAI, CAVC, RV	8m/9y	Fontan op	Palpitation	–	Twin AV node	Propafenone(–), Sotalol(+)	No Sx without medication for 3y
11	CAVC, RV	1y/9y	Fontan op	Palpitation	+	–	–	No Sx for 6y
12	CAVC, RV	2y/12y	Fontan op	Palpitation	+	SND, 2° AVB	Pacemaker	No Sx for 5 y

DIRV: double inlet right ventricle; DORV: double outlet right ventricle; RAI: right atrial isomerism; LAI: left atrial isomerism; CVAC: complete atrioventricular canal; TGA: transposition of great arteries; PA IVS: pulmonary atresia with intact ventricular septum; balanced V: balanced ventricle; RV: dominant right ventricle with rudimentary left ventricle; PO JET: postoperative junctional ectopic tachycardia; IART: intraatrial reentrant tachycardia; SND: sinus node dysfunction; AVB: AV block; PVC: premature ventricular contraction.

JT outside the immediate postoperative period. Seven out of 52 (13.5%) post-Fontan patients with heterotaxy syndrome had focal JT. Among the total Fontan survivors, paroxysmal focal JT occurred more frequently in heterotaxy syndrome than in non-heterotaxy syndrome (7/52 vs. 3/124; $p < 0.05$). The commonest anatomy of the AV junction was complete AV canal found in 8 patients. Among the Fontan survivors, paroxysmal focal JT was found more frequently in the patients with complete AV canal than in other AV junctional anomaly (8/61 vs. 2/115; $p < 0.05$). Eight out of 10 Fontan patients with late focal JT or late focal JT induction also had immediate postoperative JET after one or more cardiac surgeries, and the "JET" was atypical in 5 patients. "Atypical JET" did not respond to cooling, but was terminated by adenosine or slowed down by verapamil or diltiazem. The "atypical immediate postoperative JET" in our patients was paroxysmal and recurred later than 7 days postoperatively. We regarded patients with "atypical immediate postoperative JET" as having paroxysmal focal JT. The timing of the occurrence of JT with respect to surgery was as follows; preoperative period in 3 patients, immediate postoperative period in 5 patients, early postoperative period in 3 patients, and late postoperative period in 11 patients. We counted separately the numbers of patients whose JT occurred in the multiple time period. Four of five patients with immediate postoperative "atypical JET" recurred later, and the remaining 1 patient had focal JT induction later.

Arrhythmia Characteristics

An electrophysiologic study was performed in 11 of 12 patients. Because 9 of the 11 were in a Fontan palliation state, EP studies were limited and recording of His bundle electrogram (HBE) was very difficult. We recorded HBE during tachycardia in 3 patients. In cases without HBE, the AV interval was evaluated to document dual AV node physiology. The EP characteristics are summarized in Table 2. Evidence of twin AV nodes, defined as a changed QRS complex on ECG, Holter monitor, and/or by different site atrial pacing [7,10], was found in 4 patients (cases 3, 4, 9, 10).

Triggered or Automatic Mechanism. Among the 11 on whom EPS was performed, 6 were considered as having triggered or increased automaticity as a tachycardia mechanism. JT was induced by isoproterenol infusion alone in 1 and by rapid incremental atrial or ventricular pacing in 5 (Fig. 1). JT was not inducible by programmed stimulation, even during additional isoproterenol infusion in 2. Tachycardia was not terminated by overdrive burst pacing or a single extra-stimulus in 4 (1 induced by isoproterenol alone; 3 induced by rapid atrial pacing) (Table 2).

Focal Reentry Mechanism. Five patients had features of a reentrant mechanism. Narrow QRS tachycardia was induced reproducibly by a single atrial or ventricular extrastimulus in 3 (cases 5, 6, 7) without any AV or VA jump. His deflection preceded each QRS complex during the induced tachycardia (Fig. 2). In 4 (cases 5, 6, 8, 10), tachycardia was terminated by atrial or ventricular overdrive pacing or by a single ventricular premature beat.

Table 2. EP characteristics

Pt no.	Induction of JT	Adenosine Sensitivity	Termination by RAP/RVP	VA conduction (V pacing/JT)	RR of JT/VAe interval (ms)	Others	Possible mechanism
1	Isoproterenol	+	–	Diss/Diss	295	Dil(+), DC(–)	Automatic
2	Not induced	+	–	Diss/Diss	275–290		Automatic
3	Not induced	+	–	Diss/Diss	290		Automatic
4	–	+	–	?/Diss	360		–
5	A single, RAP, RVP	+	–/+	Wenck./1:1 , Wenck.	400–456/205	PVC-term	Reentrant
6	Single A, V	+	+/+	Decr/1:1, Wenck	305/190	PVC*	Reentrant
7	Single A	+		Diss/Diss,Wenck	313		Reentrant
8	RAP	+	+/–	Decr/1:1, Wenck	310/208	PVC; no VA adv.	Reentrant
9	RAP	+	–/?	Diss/1:1, Wenck	300/120		Auto/triggered
10	RAP	+	–/–	Diss/1:1, Wenck	312/185	PVC-term	Reentrant ?
11	RAP	+	–/?	Diss/Diss	240		Auto/triggered
12	RAP	+	?	Diss/Diss	268		Auto/triggered

JT: junctional tachycardia; A single: single atrial extrastimulus; RAP: rapid atrial pacing; RVP: rapid ventricular pacing; Decr: 1;1 VA conduction with decremental pattern; Diss.: dissociation; Wenck.: Wenckebach VA conduction; VAe: earliest VA interval; Dil(+): terminated by diltiazem; DC(–): No response to DC cardioversion; PVC-term: terminated by premature ventricular contraction; PVC*: see Figure 4.

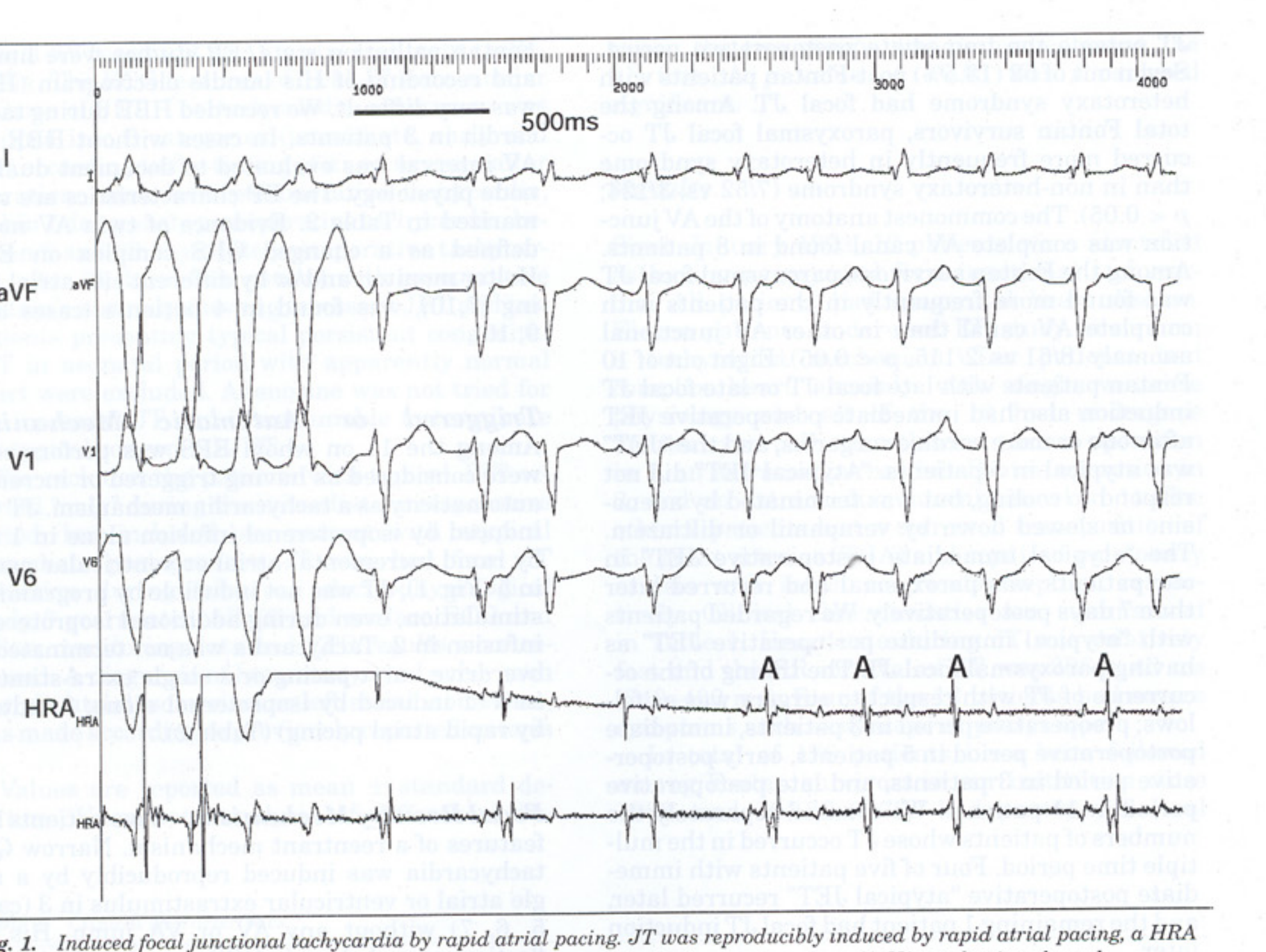

Fig. 1. Induced focal junctional tachycardia by rapid atrial pacing. JT was reproducibly induced by rapid atrial pacing, a HRA catheter was placed within the lateral tunnel Fontan pathway around atrial appendage (case 9). VA conduction showed Wenckebach's phenomenon. A: atrial electrogram.

One patient showed VA dissociation during tachycardia. Although the tachycardia showed a 1:1 VA relationship under isoproterenol infusion in 5, atrial conduction was considered as a bystander of the tachycardia because of the following observations: (1) VA block was observed after adenosine injection during the JT run (Fig. 3); (2) variable or progressive prolongation of the VA interval without any related change of tachycardia cycle length. VA interval recorded from QRS onset to the earliest atrial signal ranged from 120 to 208 ms with a mean of 184 ± 37 ms. A relatively long VA interval is suggestive of a tachycardia focus at the His bundle or less likely at the AV node level.

Case 6 with corrected TGA ({S.L.L}) showed retrograde sharp potential during tachycardia, which was recorded at morphologic left ventricular outflow tract below the pulmonary annulus. Premature ventricular contraction (PVC) given during tachycardia advanced the retrograde sharp potential by 18 ms (Fig. 4(A)). However, changes in the QRS complex as an evidence of manifest nodofascicular pathway was not observed during the tachycardia or by rapid atrial pacing. The tachycardia was terminated by an adenosine injection after sharp pathway potential to nodal conduction block (Fig. 4(B)) and the tachycardia rate was retarded by verapamil infusion. A concealed nodofascicular pathway and recording of retrograde pathway potential could explain the features of no evidence of preexcitation during rapid atrial pacing and a small advancement of the presumed pathway potential by PVC. The complicated anatomy due to atrioventricular discordance made it more difficult to record HBE and pathway potential separately and securely.

Adenosine Sensitivity

In all patients, clinical and induced JT was terminated by adenosine injection. Three Fontan palliated patients required a relatively high dose of adenosine (0.2–0.3 mg/Kg). Among the 9 with inducible JT, 3 showed a retrograde nodal block during JT by adenosine injection with or without

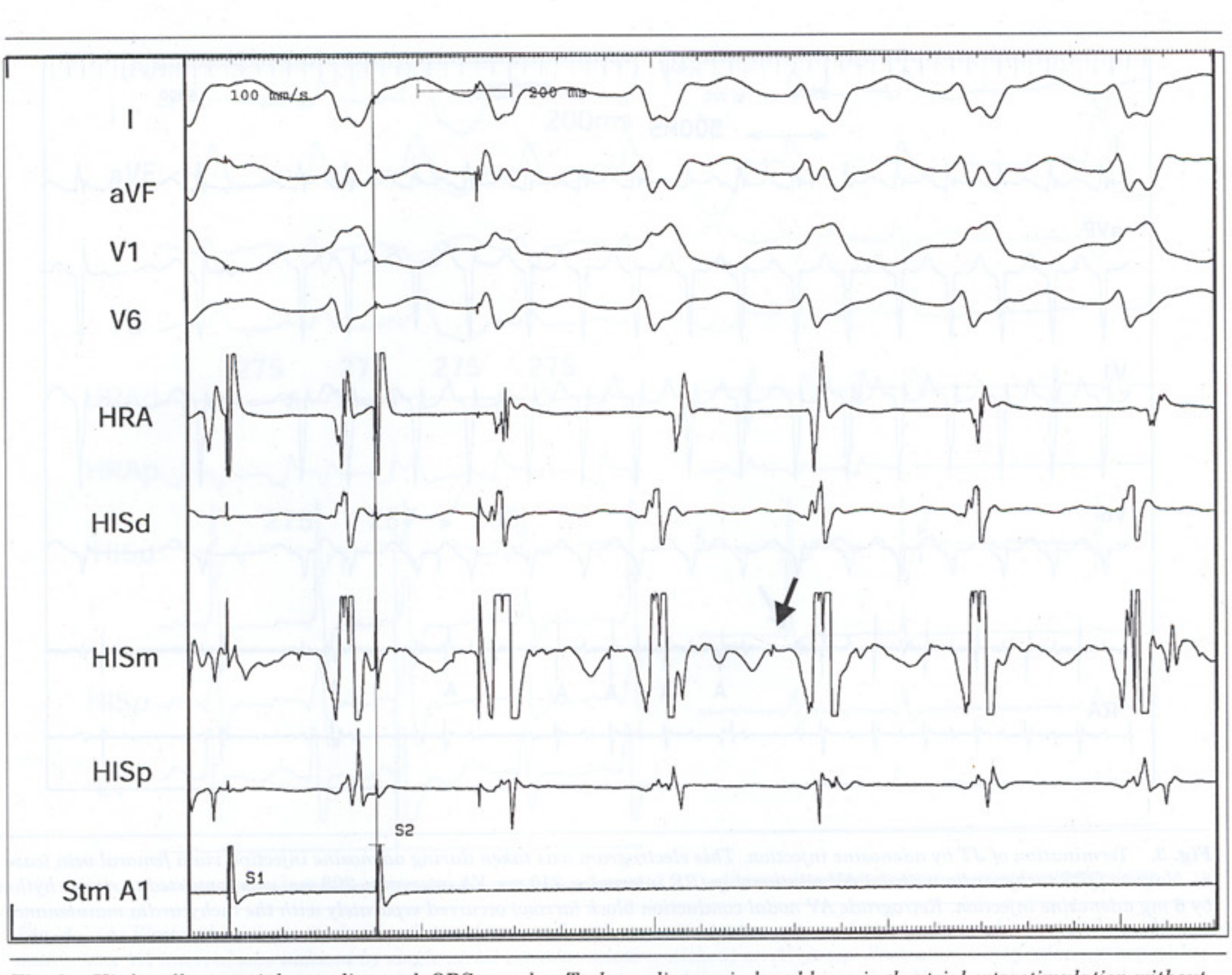

Fig. 2. His bundle potential preceding each QRS complex. Tachycardia was induced by a single atrial extrastimulation without an AH jump (case 7). Baseline ECG and tachycardia had the same QRS morphology as complete right bundle branch block. His deflection preceded each QRS complex during tachycardia.

subsequent termination of JT (Fig. 3). A differential effect of adenosine on AV node conduction and on tachycardia focus was suspected. JT did not recur immediately after adenosine wash out in all patients.

Treatment

Three patients were observed without any antiarrhythmic medication except digoxin as they had mild symptoms during tachycardia and had only one episode of documented JT. The other 9 patients complained of frequent paroxysmal palpitation attacks and were treated with antiarrhythmic medications. Class III antiarrhythmic agents (sotalol, amiodarone) were effective at suppressing symptomatic recurrence in 5 of 6 patients. In 2 of 5 patients, JT did not recur after discontinuation of medication for 3 and 8 years, respectively.

One lateral tunnel Fontan patient (Case1; double inlet right ventricle with mitral valve hypoplasia) had frequent attacks of JT with concomitant IART and sinus node dysfunction. Because he had several episodes of near syncope and had a tendency toward severe sinus bradycardia followed by junctional ectopics or runs of IART, a DDDR pacemaker was implanted and amiodarone prescribed. In spite of these measures, he revisited the emergency room almost monthly because of recurrent JT or IART. Thus, we decided to eliminate the tachycardia focus. During EPS, 2 types of rapidly conducting IART (cycle lengths of 262 and 259 ms) and rapid JT with severe hemodynamic derangement were induced. We considered mapping IART circuits difficult and dangerous and decided to ablate or modify AV node. HBE was recorded antegradely via fenestration at posterior AV groove. Because an initial attempt of AV node modification did not abolish the rapid JT, we tried a second RFCA. A complete AV block resulted 6 seconds

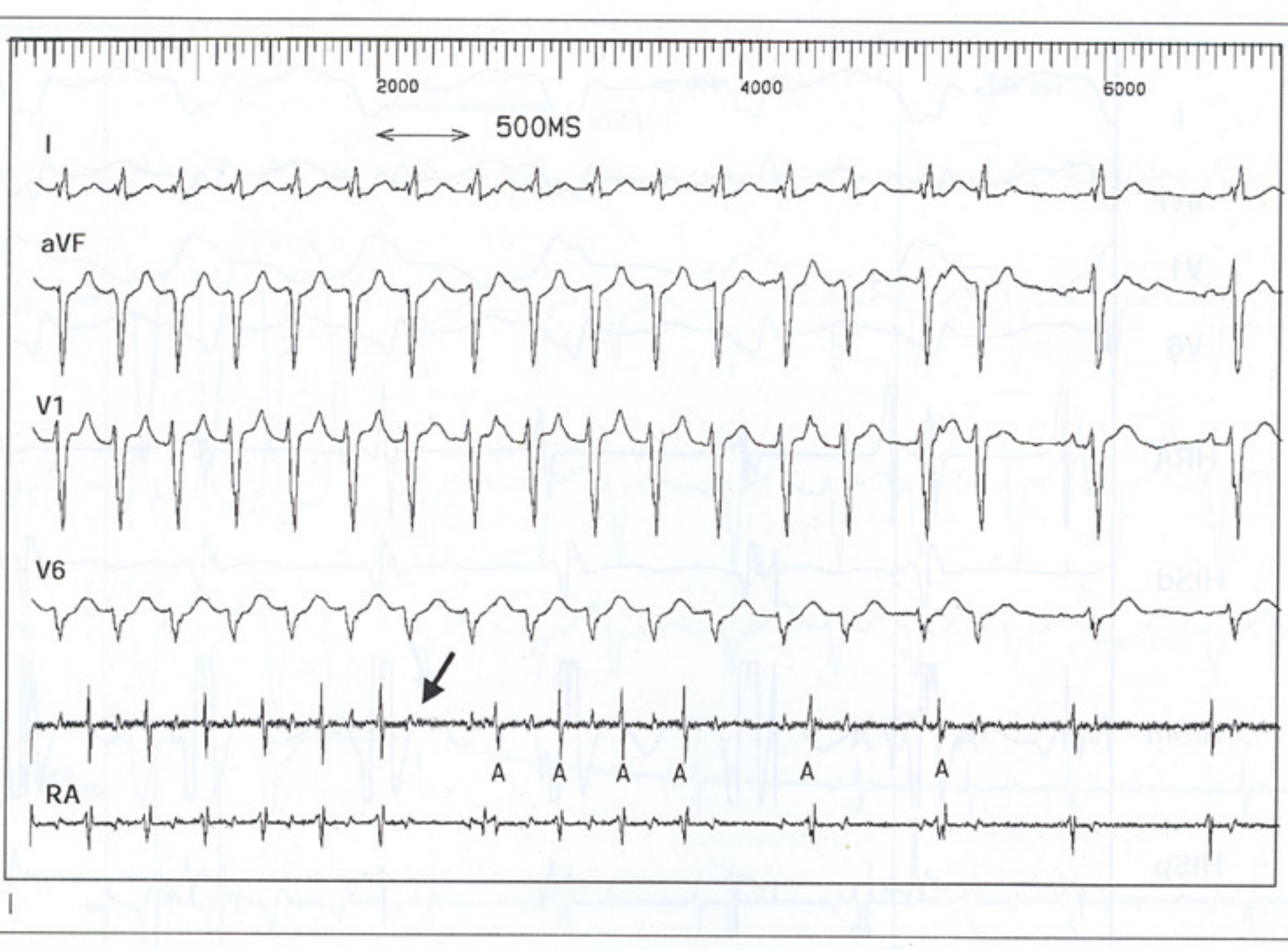

Fig. 3. Termination of JT by adenosine injection. This electrogram was taken during adenosine injection via a femoral vein (case 8). Narrow QRS tachycardia with 1:1 AV relationship (RR interval = 310 ms, VA interval = 208 ms) was converted to sinus rhythm by 6 mg adenosine injection. Retrograde AV nodal conduction block (arrow) occurred separately with the tachycardia maintenance in a short period.

after a second ablation attempt at the HBE recording site. He is doing well without any symptoms related to tachycardia over 18 months on sotalol with a pacemaker.

Discussion

We described 12 patients with paroxysmal focal junctional tachycardia. All patients had complex congenital heart disease, and the JT was sensitive to adenosine. Although ECG features are similar to JET, the JT of this report differed from JET with respect to its EP mechanism and clinical course.

JET in children falls into two main categories. The first is congenital JET, which occurs in early infancy or in children as a cause of tachycardia associated with cardiomyopathy, because it is frequently persistent or incessant [11,12]. The second is postoperative JET, which occurs immediately after congenital heart disease repair [9,11,13]. Junctional tachycardia, as a cause of late tachycardia in congenital heart disease, has not been described clearly. Although the incidence of JT was rare in patients with various congenital heart diseases, it was important enough to cause significant symptoms. Furthermore, according to our study, the incidence of JT was not rare in complete AV canal defect requiring Fontan type repair, or in heterotaxy syndrome.

The occurrence of early postoperative JET has been reported to follow any kind of palliation during the Fontan sequence, i.e., modified Blalock–Taussig shunt, pulmonary artery banding procedure, bi-directional cavopulmonary shunt operation, and modified Fontan operation in complex cardiac anomaly [9,13]. These procedures seem unrelated to direct AV junction damage. Thus, intrinsic electrophysiologic abnormalities of the AV junction might provide an underlying mechanism. Eight of a total of twelve patients had a history of JET during immediate postoperative period in this series. In 5 of them the "JET" was atypical, and this "atypical JET" did not response to cooling, but was terminated by adenosine or slowed down by calcium channel blocker. Thus the authors recommend a trial of adenosine for "JET" during the immediate postoperative period if the tachycardia

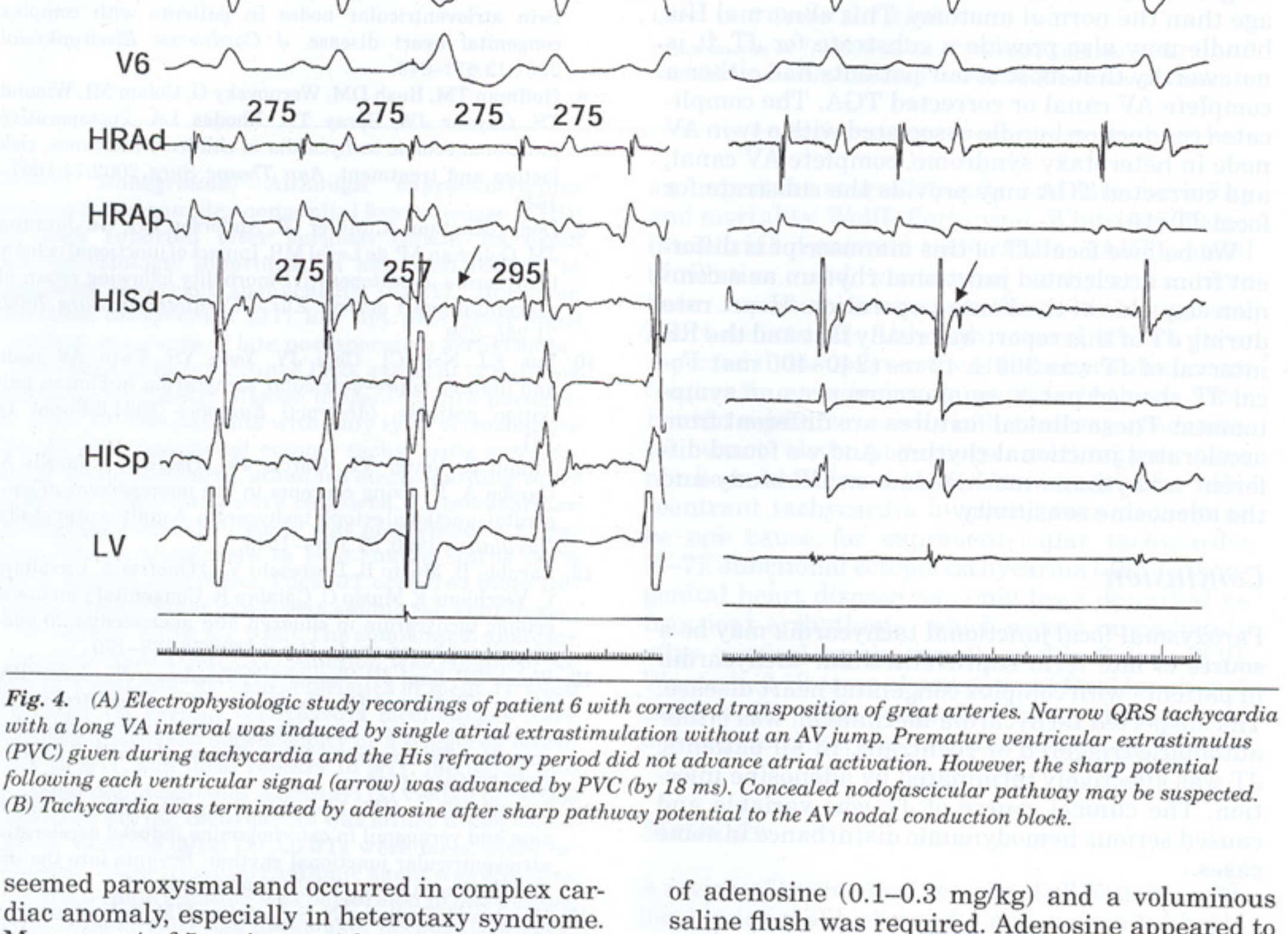

Fig. 4. (A) Electrophysiologic study recordings of patient 6 with corrected transposition of great arteries. Narrow QRS tachycardia with a long VA interval was induced by single atrial extrastimulation without an AV jump. Premature ventricular extrastimulus (PVC) given during tachycardia and the His refractory period did not advance atrial activation. However, the sharp potential following each ventricular signal (arrow) was advanced by PVC (by 18 ms). Concealed nodofascicular pathway may be suspected. (B) Tachycardia was terminated by adenosine after sharp pathway potential to the AV nodal conduction block.

seemed paroxysmal and occurred in complex cardiac anomaly, especially in heterotaxy syndrome. Moreover, 4 of 5 patients with immediate postoperative "atypical JET" recurred later. So "immediate postoperative JET" in complex anomaly may be the result of abnormal AV junctional EP characteristics in addition to possible direct surgical injury of the AV junction. In other words, such an inherent arrhythmogenic substrate may cause tachycardia during the late follow-up period, as was observed in the patients of the present study.

The mechanism of tachycardia was heterogeneous. Fifty-five percent of this small series showed features of increased automaticity or triggered activity, and 45% showed other features of reentry. However, in all cases, the rapid injection of adenosine effectively terminated the JT. In the case of Fontan circulation, because of the low flow rate and the substantial distance to the AV node from a peripheral vein, a relatively large dose of adenosine (0.1–0.3 mg/kg) and a voluminous saline flush was required. Adenosine appeared to have a differential effect on AV node and JT focus in 3 patients in this study [14]. Cyclic AMP mediated triggered activity or a small reentrant circuit involving the AV node and the His bundle, may be underlying mechanism.

Our cases with 1:1 VA conduction had a long VA interval. This observation strongly contradicts the notion that the origin of this focal junctional tachycardia is the perinodal atrial focus. Because the JT in this series seemed to have a focus at the His bundle or at the AV node level, catheter ablation of the perinodal atrium with preservation of normal AV node conduction may be less effective than in typical focal JT in the adult population [15]. The earliest retrograde atrial activation may not indicate the target site of RF ablation in cases with a long VA interval. Moreover, special anatomic abnormalities in individual case may

make it difficult to eliminate the arrhythmic focus. The abnormal location of an AV node in corrected TGA and a complex single ventricle, and the near absent interatrial septal tissue in a complete AV canal associated with heterotaxy syndrome should be considered [16–18]. The His bundle of corrected TGA and a complete AV canal is known to have a long course and to be more susceptible to damage than the normal anatomy. This abnormal His bundle may also provide a substrate for JT. It is noteworthy that most of our patients had either a complete AV canal or corrected TGA. The complicated conduction bundle associated with a twin AV node in heterotaxy syndrome, complete AV canal, and corrected TGA may provide the substrate for focal JT [10].

We believe focal JT of this manuscript is different from accelerated junctional rhythm as a common sequelae of the Fontan operation. Heart rate during JT of this report was really fast and the RR interval of JT was 306 ± 42 ms (240–400 ms). Focal JT showed paroxysmal occurrence and symptomatic. These clinical features are different from accelerated junctional rhythm. And we found different arrhythmia mechanisms on EP study and the adenosine sensitivity.

Conclusion

Paroxysmal focal junctional tachycardia may be a source of late term supraventricular tachycardia in patients with complex congenital heart disease. The suspected tachycardia mechanism was either automatic/triggered or reentrant. In all patients, JT was effectively terminated by adenosine injection. The clinical course of JT was variable and caused serious hemodynamic disturbance in some cases.

References

1. Walsh EP. Arrhythmias in patients with congenital heart disease. *Card Electrophysiol Rev* 2002;6:422–430.
2. Wu MH, Wang JK, Lin JL, Lai LP, Lue HC, Hsieh FJ. Cardiac rhythm disturbances in patients with left atrial isomerism. *PACE* 2001;24:1631–1638.
3. Stamm C, Friehs I, Duebener LF, Zurakowski D, Mayer JE Jr, Jonas RA, del Nido PJ. Improving results of the modified Fontan operation in patients with heterotaxy syndrome. *Ann Thorac Surg* 2002;74:1967–1978.
4. Cheung Y, Cheng VY, Yung T, Chau AK. Cardiac rhythm and symptomatic arrhythmia in right atrial isomerism. *Am Heart J* 2002;144:159–164.
5. Saul JP, Walsh EP, Triedman JK. Mechanisms and therapy of complex arrhythmias in pediatric patients. *J Cardiovasc Electrophysiol* 1995;6:1129–1148.
6. Wu MH, Wang JK, Lin JL, Lai LP, Lue HC, Young ML, Hsieh FJ. Supraventricular tachycardia in patients with right atrial isomerism. *J Am Coll Cardiol* 1998;32:773–779.
7. Epstein MR, Saul JP, Weindling SN, Triedman JK, Walsh EP. Atrioventricular reciprocating tachycardia involving twin atrioventricular nodes in patients with complex congenital heart disease. *J Cardiovasc Electrophysiol* 2001;12:671–679.
8. Hoffman TM, Bush DM, Wernovsky G, Cohen MI, Wieand TS, Gaynor JW, Spray TL, Rhodes LA. Postoperative junctional ectopic tachycardia in children: Incidence, risk factors and treatment. *Ann Thorac Surg* 2002;74:1607–1611.
9. Dodge-Khatami A, Miller OI, Anderson RH, Gil-Jaurena JM, Goldman AP, de Leval MR. Impact of junctional ectopic tachycardia in postoperative morbidity following repair of congenital heart defects. *Eur J Cardiothorac Surg* 2002; 21:255–259.
10. Bae EJ, Noh CI, Choi JY, Yoon YS. Twin AV node and induced supraventricular tachycardia in Fontan palliation patients. *(Abstract) Europace* 2004;6(Suppl I): 191.
11. Villain E, Vetter VL, Garcia JM, Herre J, Cifarelli A, Garson A. Evolving concepts in the management of congenital junctional ectopic tachycardia. A multicenter study. *Circulation* 1990; 81:1544–1549.
12. Sarubbi B, Musto B, Ducceschi V, D'Onofrio A, Cavallaro C, Vecchione F, Musto C, Calabro R. Congenital junctional ectopic tachycardia in children and adolescents: 20 year experience based study. *Heart* 2002;88:188–190.
13. Walsh EP, Saul JP, Sholler GF, Triedman JK, Jonas RA, Mayer JE, Wessel DL. Evaluation of a staged treatment protocol for rapid automatic junctional tachycardia after operation for congenital heart disease. *J Am Coll Cardiol* 1997;29:1046–1053.
14. Lee KL, Chun HM, Liem LB, Sung RJ. Effect of adenosine and verapamil in catecholamine induced accelerated atrioventricular junctional rhythm: Insights into the underlying mechanism. *PACE* 1999;22:866–870.
15. Handan H, Badhwar N, Scheinman MM. Role of invasive electrophysiologic testing in the evaluation and management of adult patients with focal junctional tachycardia. *Card Electrophysiol Rev* 2003;6:431–435.
16. Anderson RH, Becker AE, Arnold R, Wilkinson JL. The conducting tissues in congenitally corrected transposition. *Circulation* 1974;50:911–923.
17. Dickinson DF, Wilkinson JL, Anderson KR, Smith A, Ho SY, Anderson RH. The cardiac conduction system in situs ambiguus. *Circulation* 1979;59:879–885.
18. Ho SY, Fagg N, Anderson RH, Cook A, Allan L. Disposition of the atrioventricular conduction tissues in the heart with isomerism of the atrial appendages: Its relation to congenital complete heart block. *J Am Coll Cardiol* 1992;20:904–910.