Twin AV Node and Induced Supraventricular Tachycardia in Fontan Palliation Patients

EUN-JUNG BAE,* CHUNG-IL NOH,* JUNG-YUN CHOI,* YONG-SOO YUN,* WOONG-HAN KIM,† JEONG-RYUL LEE,† and YONG-JIN KIM†

From the *Department of Pediatrics, and †Department of Thoracic Surgery, Seoul National University Children's Hospital, Seoul, South Korea

BAE, E-J., ET AL.: Twin AV Node and Induced Supraventricular Tachycardia in Fontan Palliation Patients. ***Introduction:*** *The coexistence of two distinct atrioventricular (AV) nodes has been described in congenital heart disease requiring Fontan type palliation. The purpose of this study was to evaluate the occurrence of twin AV node according to anatomical subgroups, and to determine its relation to tachycardia.*

Methods: *From 2001 to 2003, we performed an electrophysiologic (EP) study upon 52 consecutive patients who had undergone cardiac catheterization after Fontan completion. Atrial pacing was performed at three or more different atrial sites.*

Results: *In 10/52 patients, two different QRS complexes were recorded at different pacing sites, suggesting twin AV node (9/20 in right isomerism, 1/8 discordance AV connections, 0/24 other complex anomalies). AV reciprocating tachycardia (AVRT), presumably involving two AV nodes and a connecting sling, was induced in 6 of 10 patients who had twin AV node (4/6 used posterior AV node as an antegrade limb, 2/6 used an anterior AV node as an antegrade limb). Heterotaxy syndrome ($P < 0.001$) and complete AV septal defect ($P = 0.002$) were found to be risk factors for twin AV node. Junctional tachycardia (JT; HR > 150/min) with either VA dissociation (7/9) or second degree VA block (2/9) were induced by pacing or isoproterenol infusion in 9/52 patients.*

Conclusion: *JT induction was associated with a twin AV node ($P = 0.04$), or a history of early postoperative junctional ectopic tachycardia ($P = 0.02$). A complicated AV node conduction system such as twin AV node was frequent in heterotaxy syndrome. Both AVRT and JT with VA block may be important causes of tachyarrhythmia in this patient group. (PACE 2005; 28:126–134)*

atrioventricular node, tachycardia, heterotaxy syndrome, right isomerism, Fontan operation

Introduction

Tachyarrhythmia is a troublesome complication of palliated or repaired congenital heart disease. Moreover, this would be additionally harmful to patients with a suboptimal hemodynamic status after a Fontan type repair. Supraventricular tachycardia is reported to be very frequent in heterotaxy syndrome.[1] Complex cardiac anomaly associated with heterotaxy syndrome may have an inherent substrate for supraventricular tachycardia. The atrioventricular (AV) node and conduction bundle abnormality has been described in a few cases as a particular finding of complex cardiac anomaly by autopsy studies.[2–7] Several electrophysiological studies have reported on cases with two separate AV nodes and AV reciprocating tachycardia (AVRT) involving two AV nodes.[1,8–11]

This study was performed to evaluate the occurrence of twin AV node according to anatomical subgroups, and to determine its relation to tachycardia in complex cardiac anomaly of a single ventricular physiology.

Methods

Study Population

From January 2001 to October 2003, we conducted an intracardiac electrophysiologic (EP) study upon 52 consecutive patients who underwent cardiac catheterization after Fontan completion. The indications of cardiac catheterization were a routine follow-up study (n = 30); hypoxemia because of fenestration, baffle leak, or venous collaterals (n = 14); hemoptysis (n = 2), heart failure (n = 4), or a protein losing enteropathy (n = 2). From January 1987 to December 2000, 216 patients survived the Fontan operation. Among them, 176 patients were followed at this institution. Cardiac catheterization procedures were recommended to all patients and 52 cases (29.5%) were enrolled in this study. An EP study was done after approval of ethical committee of the institution and informed consent was obtained in all 52 patients. The age of the patients was 10.3 ± 5.3 years (2–26 years), age at Fontan operation was 4.2 ± 4.1

This manuscript was partly supported by a grant from the SNU Pediatrics Alumni Association.

Address for reprints: Eun-Jung Bae, Department of Pediatrics, Seoul National University Children's Hospital, 28 Yongon-dong, Chongro-gu, Seoul 110-744, South Korea. Fax: 82-2-743-3455; e-mail: eunjbae@plaza.snu.ac.kr

Received July 13, 2004; revised September 17, 2004; accepted November 23, 2004.

years (1–20 years), and the duration of follow-up after the Fontan operation was 6.2 ± 3.7 years (0–13 years). The types of Fontan operations were as follows; atriopulmonary connection (n = 7), lateral tunnel operation (n = 37), and extracardiac conduit Fontan operation (n = 8). A review of medical records and 12-lead surface ECG, all rhythm strips and Holter monitoring were performed. Any changes in QRS morphologies were sought. A diagnosis of a cardiac anomaly was based on a combination of echocardiographic and available computed tomography or magnetic resonance imaging results.

The morphologic diagnoses are summarized in Table I. Heterotaxy syndrome was defined as the presence of a pattern of typical cardiac, vascular, and visceral abnormalities that indicated abnormal sidedness of right isomerism or left isomerism. A diagnosis of right isomerism or left isomerism was made according to previously reported criteria.[1]. Among 52 patients, there were 18 right isomerisms and 2 left isomerisms.

Table I.
Morphological Characteristics of the 52 Patients

Visceroatrial situs	
Ambiguous	20 (38%)
Right isomerism	18
Left isomerism	2
Solitus	22 (43%)
Inversus	10 (19%)
Atrioventricular connections	
Concordant	39 (75%)
Discordant	8 (15%)
Ambiguous	5 (10%)
Atrioventricular junctional anomaly	
Tricuspid atresia or mitral atresia	5 (10%)
Single indeterminate AV valve*	7 (12%)
Double inlet right ventricle	19 (37%)
Double inlet left ventricle	4 (8%)
Criss cross AV connections	2 (4%)
Biventricular 2 valves	5 (10%)
Biventricular common valve	10 (19%)
Complete AVSD†	18 (35%)
Ventriculoarterial connections	
DORV	35 (67%)
Concordant	6 (12%)
Discordant	11 (21%)

AV = atrioventricular; DORV = double outlet of right ventricle.
*All single indeterminate AV valve was considered to have single morphologic right ventricle without documented rudimentary left ventricle.
†AVSD = atrioventricular septal defect, 14/18 patients with complete AVSD had right isomerism, balanced two ventricles were found in 10/18, dominant right ventricle with double inlet right ventricle was found in 8/18.

Electrophysiologic Study

Electrophysiologic study was performed after hemodynamic study and angiography, but before intervention in a conscious midazolam-sedated state. Two quadripolar catheters were introduced into the Fontan pathway and the systemic ventricle, respectively. In eight patients, a transesophageal lead was also placed. The range of pulse duration was between 1.9 and 9.9 ms and output was between 3.0 and 15.0 mA according to sites and capture thresholds. Twelve-lead ECG were obtained during atrial pacing, which were faster than the baseline rate by 10% at three or more different atrial sites (high RA and low RA directly and high LA and low LA via fenestration, coronary sinus, or esophagus). Both atrial and ventricular programmed electrical stimulations were performed with or without isoproterenol infusion (0.02–0.05 mcg/kg per minute).

Statistical Analysis

Values are reported as mean ± standard deviation. Univariate analysis of differences between the two groups was performed using the chi square test. A P value <0.05 was considered as significant.

Results

Baseline Measurement

The baseline rhythm was sinus or atrial rhythm in 45, sinus bradycardia with intermittent junctional acceleration was observed in 7. The PR interval was 153.2 ± 42.7 ms (110–290 ms), and QRS duration 96.6 ± 15.7 ms (70–120 ms). The QRS axis was superior in 25, 0–90° in 12, and 90–180° in 15 at baseline. The angle of the QRS-T wave was 123.1 ± 55.9. In 12 of 52 patients, significant ST depression was observed by more than 1 mm in limb leads, and more than 2 mm in precordial leads.

Changes of QRS Complexes as an Evidence of a Twin AV Node

Changes of QRS complexes during sinus rhythm in routine ECGs or by Holter monitoring occurred in 13 patients (25%). Eight of them had two types of QRS with a superior axis and an inferior axis, and two of them had two different QRS with a superior axis. In the remaining three patients, the axes could not be defined because the only positive recordings were taken during Holter monitoring. Two patients out of 13 patients had ECG characteristics of a normal PR interval, slurred QRS upstroke, and QRS widening intermittently; however, the presence of Mahaim fiber was not verified during EP study.

During continuous atrial pacing, two different QRS complexes were observed dependent upon

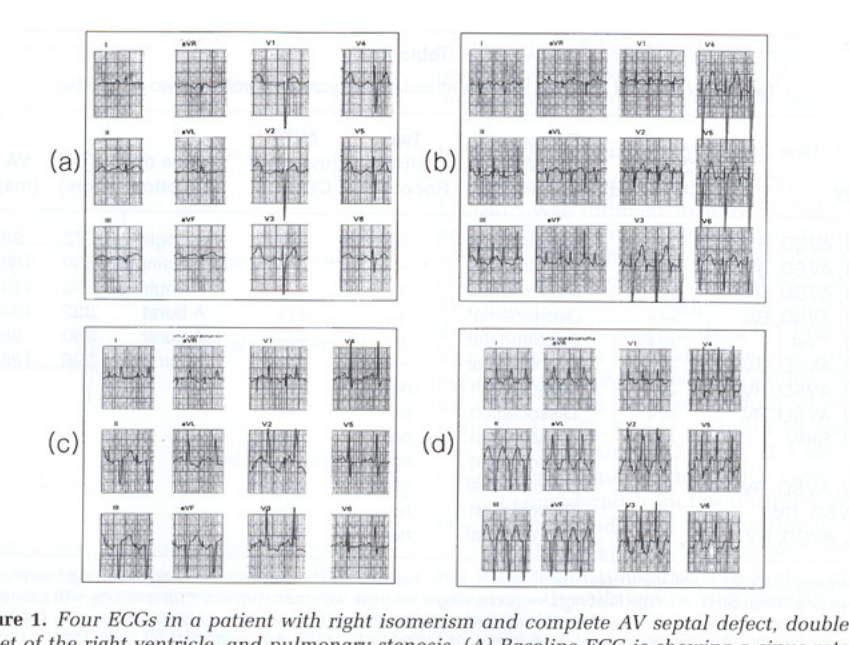

Figure 1. *Four ECGs in a patient with right isomerism and complete AV septal defect, double outlet of the right ventricle, and pulmonary stenosis. (A) Baseline ECG is showing a sinus rate with low voltage QRS in limb leads with a QRS axis of 0. (B) ECG taken during high atrial pacing, showing that the axis of QRS complex has changed. (C) ECG taken during low atrial pacing demonstrating a distinctly different non-preexcited QRS complex; negative in lead II, III, aVF, leftward axis, and counterclockwise looping in the frontal plane suggesting AV conduction through the posterior AV node. (D) ECG during induced supraventricular tachycardia; QRS complexes are the same as those of low atrial pacing shown in (C) indicating that the AV reentrant tachycardia was using the posteriorly located AV node as antegrade limb.*

the pacing site. The different QRS complexes were non-preexcited and had a normal QRS duration. The QRS changes were considered as an evidence of two separate AV nodes, because the change was a function of pacing location rather than pacing rate. QRS changes were observed during pacing study in 10 of the 52 patients (19.2%) including 9/20 (45%) with heterotaxy syndrome, 1/8(13%) in discordance AV connections, and 0% in other abnormalities. Three of 13 patients with changed QRS on surface ECG did not show different QRS morphology by multisite atrial pacings. In 3 of 10 patients who had two paced QRS morphologies, the baseline QRS seemed to be fused, because the two QRS morphologies created by either high or low atrial pacing differed from baseline QRS (Fig. 1). All 52 patients had either VA dissociation (n = 30) or decremental VA conduction (n = 22) by V pacing.

The risk of having twin AV nodes was higher in heterotaxy syndrome (45%; 95% CI 2.9–62.7; P < 0.001), and in complete AV septal defect (39%; 95% CI 2.4–51.8; P = 0.002). A history of postoperative JET had a weak associated risk (54%; 95% CI 1.0–20.4; P = 0.057). Complicated AV discordance requiring single ventricular repair was not found to carry a risk of having twin AV nodes (P = 0.38). Other AV junctional abnormalities, sinus node dysfunction, PR prolongation, QRS axis, surgical types of Fontan operations were all not associated with twin AV node.

Electrophysiological Characteristics of Twin AV Node and of AV Reciprocating Tachycardia

AV reciprocating tachycardias presumably involving two different AV nodes were induced in 6 of 10 patients who showed two different paced QRS morphologies. Four of six patients with induced AVRT had histories of clinical narrow QRS tachycardia. Four of six patients who had induced AVRT used the posterior node as the antegrade limb, and two of six patients used the anterior node as the antegrade limb during tachycardia. The AV node used as antegrade limb was determined according to QRS morphology (6/6) and normal HV intervals (4/6). The EP characteristics of twin AV node and tachycardia are summarized in Table II. An aggressive attempt was made to record two

Table II.
Twin AV Node and Induced Supraventricular Tachycardia Involving Two AV Nodes

Morphology	2 QRS (ECG/Paced)	Retrograde VA Conduction	Two HBE Recorded	AVRT (Induced/ Clinical)	Mode of Induction	TCL (ms)	VA (ms)	Antegrade Limb
{A.D.D}, RI, AVSD, BV	+/+	Decremental	+	+/+	V single	272	98	Post.
{A.D.D}, RI, AVSD, BV	+/+	Decremental	–	+/+	A & V single	330	188	Ant.
{A.D.D}, RI, AVSD, RV	+/+	Decremental	+	+/+	V single	330	113	Ant.
{A.D.D}, RI, AVSD, BV	+/+	Decremental	+	+/+	A burst	332	164	Post.
{A.D.D}, RI, TVst.	+/+	Decremental	+	+/–	A burst	280	98	Post.
{A.D.D}, RI, AVSD, BV	+/+	Decremental	–	+/–	A burst	296	128	Post.
{A.D.D}, RI, AVSD, RV	+/+	Dissociation	ne	–/–				
{A.D.D}, RI, AVSD, RV	+/+	Dissociation	ne	–/–				
{A.D.D}, RI, SIRV	+/+	Dissociation	ne	–/–				
{I.D.D}, TA	+/+	Dissociation	ne	–/–				
{A.D.D}, RI, AVSD, RV	±	Decremental	ne	–/–				
{S.D.D}, AVSD, RV	±	Dissociation	ne	–/–				
{A.L.L}, RI, AVSD, BV	±	Decremental	ne	–/–				

RI = right isomerism; AVSD = atrioventricular septal defect; BV = balanced both ventricles; RV = dominant right ventricle; TVst. = tricuspid valve straddling; SIRV = single inlet right ventricle, single ventricle with right ventricular morphology with indeterminate single AV valve; TA = tricuspid atresia; AVRT = atrioventricular reciprocating tachycardia involving a twin AV node; ne = not evaluated; TCL = tachycardia cycle length; VA = ventriculo-atrial conduction time during tachycardia; Ant. = anterior AV node; Post. = posterior AV node; JT = junctional tachycardia.

separate His-bundle potentials in six patients who had induced AVRT (Fig. 2). The whole AV annulus was mapped with special attention to the posterior and anterior extents of the ventricular septum relative to the AV junction, according to both the echocardiographic and angiographic position of the interventricular septum. Both anterior and posterior His-bundle electrograms were recorded

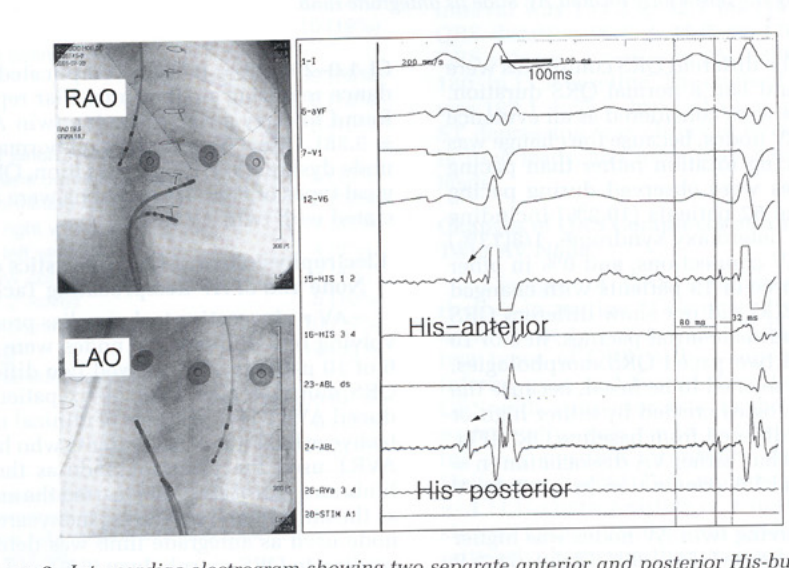

Figure 2. *Intracardiac electrogram showing two separate anterior and posterior His-bundle potentials of twin AV node during sinus rhythm. Electrode catheters were introduced through the fenestration and baffle leak in this patient (RAO = right anterior oblique view, LAO = left anterior oblique view).*

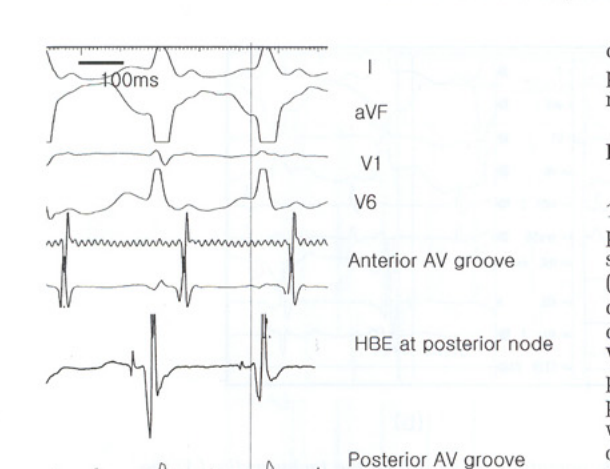

Figure 3. *Surface ECG and intracardiac electrograms taken during AV reciprocating tachycardia. Although the recordings could not be taken simultaneously because of limitation of catheter access, the AV junctions around the anterior and posterior AV nodes were mapped during the same tachycardia. During AV reciprocating tachycardia, the atrial activation of the anterior node was earlier than that of posterior node in this patient. Posterior His was earlier than anterior His. Retrograde conduction through the anterior node was suspected.*

in four patients through the fenestration or baffle leak of the Fontan pathway antegradely, or by the retrograde approach using a deflectable quadripolar catheter. The HV interval of the dominant node during sinus rhythm was 48 ± 9 ms (32–68 ms). There were no AH jump during programmed atrial extrastimulation studies in all patients. Tachycardia was induced following an abrupt block of the retrograde conduction of one AV node by single V extra-stimulation in three patients and by burst A pacing in three patients. During tachycardia, atrial activation signals around the position of retrograde AV node were earlier than that of antegrade AV node (Fig. 3). During AV reciprocating tachycardia, the HBE functioning as retrograde limb was later than that of the antegrade limb, but earlier than the local ventricular signals in all four patients with His-bundle recording (Fig. 4). The short positive HV interval corresponding to the anterior node (retrograde limb) cannot correspond to retrograde conduction from ventricle → His bundle → AV node. This observation could be explained by antegrade conduction through posterior AV node followed by nearly simultaneous activation of anterior His (via connecting sling) and posterior bundle branches and ventricular myocardium. All four patients with connecting sling had right atrial isomerism with complete AV septal defect.

Induced Junctional Tachycardia with VA Block

Junctional tachycardia (JT) faster than 150/min was induced in 9/52 (17%) patients by programmed atrial or ventricular stimulation, or spontaneously after the infusion of isoproterenol (Fig. 5). All induced JT except two showed VA dissociation, and the other two showed second degree VA block during the JT. Clinical JT with VA dissociation beyond the early postoperative period was found in 6 patients among the 52 study patients. JT was induced in four of six patients with clinical JT. Thus, a total of 11 had induced or clinical JT. Among 7 of 11 JT cases, twin AV nodes were demonstrated. QRS complex during JT was considered from the posterior AV node in five patients, and from the anterior node in two. The EP characteristics are summarized in Table III. Adenosine injection was highly effective to terminate the clinical or induced JT in 7/7 tried patients.

Risk factors for JT, clinical or induced JT beyond early postoperative period, were twin AV node (50.0%; 95% CI 1.3–29.4; P = 0.04), a history of early postoperative JET (54.5%; 95% CI 1.4–33.9; P = 0.02). Heterotaxy syndrome, AV discordance, other AV junctional abnormalities, sinus node dysfunction, PR prolongation, QRS axis, surgical types of Fontan operations, atrial septectomy, AV valve repair, induced AV reentrant tachycardia, and age were all not associated with late postoperative JT.

Discussion

Tachyarrhythmia is one of the most dangerous complications in Fontan palliation patients. Postoperative intraatrial reentrant tachycardia is a well-known arrhythmia in this disease group. However, other supraventricular tachycardia may cause additional rhythm problems.[1,8,11] By pathologic analysis of autopsy specimens, two separate AV nodes and abnormal conduction bundle and connecting sling were described as characteristics of congenital heart disease with discordance AV connections or heterotaxy syndrome.[2,3,6] The combination of L-Loop ventricle and complete AV septal defect were believed to be the morphologic substrate for twin AV node by Epstein et al.[12] In our series, both heterotaxy syndrome and complete AV septal defect were found to increase the risk of having a twin AV node. We excluded heterotaxy syndrome of right isomerism or left isomerism from AV discordance, because both atria would be either the two right or the two left atria.

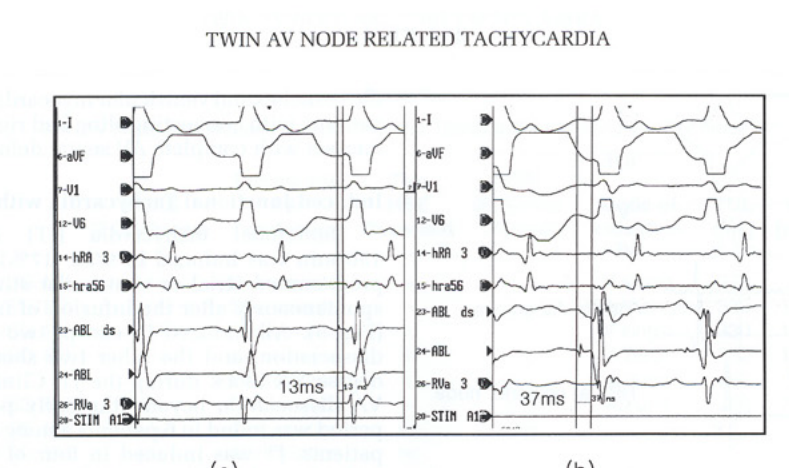

Figure 4. *Recordings of the two separate His potentials taken during the tachycardia: (A) the ABL catheter was located near the anterior node on the left side recording, and (B) near the posterior node on the right side recording. Local ventricular activation around posterior node during tachycardia is earlier than that of ventricular apex and anterior node. HBE presumed to be retrograde limb (A) was later than that of the antegrade limb (B) by 24 ms, but earlier than the local ventricular signal. Probably a sling of conduction bundle connected the posterior and anterior His bundles.*

"Internodal tachycardia," or AVRT using twin AV node has been described in several reports.[1,8,12] They believed that tachycardia involves one AV node as an antegrade limb and the other node as a retrograde limb. Wu et al. speculated that unidirectional conduction may be a common property of twin AV nodes.[8] However, in this series all six patients with induced AVRT had two different paced QRS complexes. Thus bidirectionally conducting node may function as one limb according to the different AV node effective refractory periods between twin node antegradely or retrogradely. Previous studies failed to demonstrate the presence of a connecting sling by EP study. The fact that retrograde HBE precedes the local V potential of the electrode catheter positioned at the retrograde limb during "internodal tachycardia" strongly suggests the presence of a rapid conducting bundle

Table III.
Induced and Clinical Junctional Tachycardia

	Induced JT	Clinical JT	Early Postop. JET	2QRS (ECG/ Paced)	JT RR Interval (ms)	VA Relation	Mode of Induction	Position of AV Node	Mode of Termination
1	+	+	+	+/+	396	2° VAB	A single & burst	Post.	Ad(+), B(–)
2	+	+	–	+/+	320	Dissociation	V single	Post.	S
3	+	+	+	–/–	270	Dissociation	Isoproterenol	–	Ad(+), V(+), DC(–)
4	+	–	+	–/–	240	Dissociation	A burst	–	Ad(+), B(–)
5	–	+	+	+	280	Dissociation	–	Post.	Ad(+), DC(–)
6	+	–	–	–/–	258	Dissociation	V double	–	S
7	+	–	–	+/+	320	Dissociation	Isoproterenol	Post.	Ad(+)
8	+	–	+	+/–	268	Dissociation	A burst		S
9	+	–	+	+/+	400	Dissociation	A single	Post.	Ad(+), S, B(–)
10	–	+	–	+/–	310	Dissociation	–	Ant.	Ad(+)
11	+	+	–	+/+	340	2° VAB	A burst	Ant.	S

JT = junctional tachycardia; Postop. JET = postoperative junctional ectopic tachycardia; VA relation = ventriculo-atrial relation during tachycardia; A = atrial; V = ventricular; Ant. = anterior node; Post. = posterior node; Ad = adenosine; B = burst pacing; S = spontaneous; V = verapamil; DC = DC cardioversion.

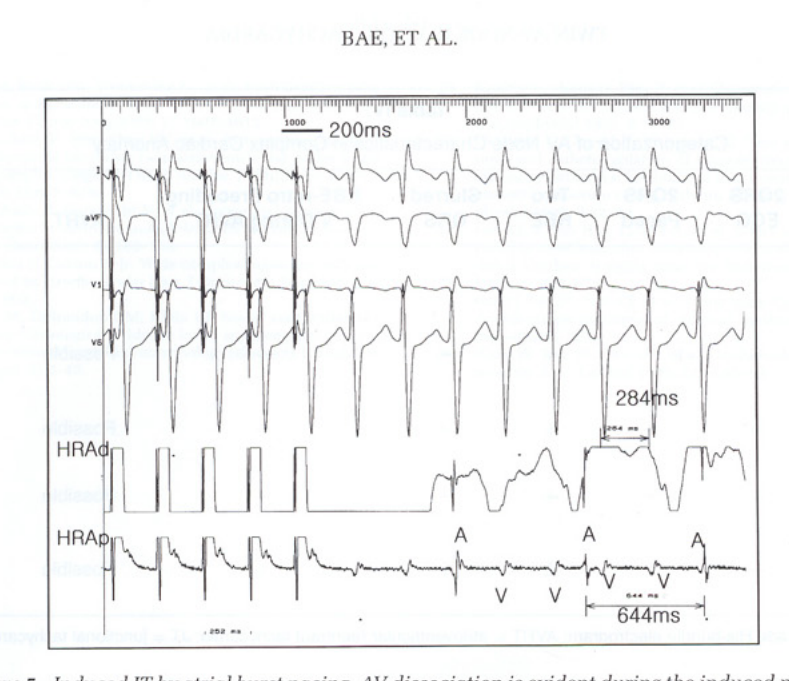

Figure 5. *Induced JT by atrial burst pacing. AV dissociation is evident during the induced narrow QRS tachycardia (HRAd = distal high right atrium; HRAp = proximal right atrium; A = atrial electrogram; V = ventricular electrogram).*

between the two AV nodes (Mönkeberg's sling) (Fig. 4). Evidence of connecting sling was found in four "internodal tachycardia" with HBE recorded, and all four patients had right isomerism with complete AV septal defect. Although one solitary right ventricle of single inlet right ventricle had two paced QRS morphologies, no tachycardia was induced during programmed pacing study.

Narrow QRS tachycardias with VA dissociation were induced frequently (9/52) in this series. Clinically documented late-term postoperative JT was not rare (6/52). Although ECG characteristics were not different from junctional ectopic tachycardia, the inducibility and high sensitivity to adenosine (7/7) may indicate another EP mechanism. Congenital JT in the structurally normal heart is very rare, is frequently incessant, and is adenosine insensitive.[13] The clinical JT in this series showed paroxysmal and recurrent episodes. The differential diagnosis for narrow QRS tachycardia with AV dissociation includes: automatic junctional tachycardia, concealed nodofascicular, AV nodal reentry with a final upper common pathway block.[14–17] The major mode of JT induction in this study was burst A pacing or isoproterenol infusion (6/9 patients), and the majority had a tendency to terminate by adenosine injection or spontaneously. Triggered or increased automaticity may be a mechanism.[18] The early postoperative junctional ectopic tachycardia in the Fontan sequence may be associated with an abnormal AV junctional anatomy and abnormal electrophysiological characteristics rather than with surgical injury of the AV junction.

The anatomical and electrophysiological characteristics of the AV junction of the functionally single ventricle requiring Fontan operation could be categorized as follows (Table IV).

1. One AV node and a conduction bundle.
2. Two AV nodes and different conduction bundles with a connecting sling.
3. Two AV nodes and different conduction bundles without a connecting sling.
4. Two AV nodes with a common conduction bundle.
5. One dominant AV node with a nodofascicular, nodoventricular, or fasciculoventriclar pathway.

These abnormal anatomy and electrophysiology of AV junction may provide a substrate for supraventricular tachycardia such as " internodal tachycardia" or JT with AV dissociation.

Limitations of this Study

First of all, this is not a randomized blind controlled study. Although we recommended

Table IV.
Categorization of AV Node Characteristics in Complex Cardiac Anomaly

	2QRS ECG	2QRS Paced	Two HBE	Slurred QRS	HBE-retro Preceding V During AVRT	AVRT	JT with AV Dissociation
1	–	–	–	–	–	–	Possible
2	+	+	+	–	+	Possible	Possible
3	+	+	+	–	–	Possible	Possible
4	–	–	+	–	+	Possible	Possible
5	+	±	±	+	+	Possible	Possible

HBE-retro = retrograde His-bundle electrogram; AVRT = atrioventricular reentrant tachycardia; JT = junctional tachycardia.

cardiac catheterization to all patient unselectively, there would be a tendency for patients with complications to undergo cardiac catheterization and EP study. Second, we tried to estimate the incidence of twin AV node among patients with single ventricle physiology. However, the proportion of heterotaxy syndrome (38%) is pretty high in the study population. There might be some racial difference. Heterotaxy syndrome was present in 38% in repaired patients with Fontan operation and 68% in double inlet ventricle in Asian population.[19,20] Third, we could not record HBE in every patient because of catheter manipulation difficulties and prolonged procedure time. Thus, the EP studies were limited. However, multisite atrial pacing and both atrial and ventricular pacing study were possible. Fourth, we did not map the whole atrium and ventricle, and thus, the entire conduction sequence of suspected "internodal tachycardia" was not demonstrated. However, we recorded atrial signals at both the anterior node and the posterior node sequentially during the same tachycardia, and AVRT involving two separate AV nodes could be considered as a diagnosis. Future efforts to gather a more convincing map with three-dimensional electro-anatomic display are required. Fifth, the morphologic diagnosis of the heart was made mostly by echocardiography. Sometimes the morphology of AV valve and ventricle was hard to determine especially when rudimentary chamber was not found.

In conclusion, a complex AV node conduction system, such as a twin AV node with two conduction bundles, connecting sling, is not rare in cardiac anomaly requiring Fontan type palliation. Heterotaxy syndrome and complete AV septal defect showed a risk for twin AV node. Both AVRT involving twin AV node and JT with AV dissociation may be important causes of tachyarrhythmia in this patient group.

References

1. Wu MH, Wang JK, Lin JL, et al. Supraventricular tachycardia in patients with right atrial isomerism. J Am Coll Cardiol 1998; 32:773–779.
2. Mönckeberg JG. Zur entwicklungsgeschichte des atrioventrikularsystems. Verhandl Deutsch Path Gesellsch 1913; 16:228–249.
3. Anderson RH, Becker AE, Amold R, et al. The conducting tissues in congenitally corrected transposition. Circulation 1974; 50:911–923.
4. Wenink ACG. Congenitally complete heart block with an interrupted Mönckeberg sling. Eur J Cardiol 1979; 9:89–99.
5. Symons JC, Shinebourne EA, Joseph MC, et al. Criss-cross heart with congenitally corrected transposition: Report of a case with d-transposed aorta and ventricular preexcitation. Eur J Cardiol 1977; 5:493–505.
6. Dickinson DF, Wilkinson JL, Anderson KR, et al. The cardiac conduction system in situs ambiguus. Circulation 1979; 59:879–885.
7. Ho SY, Fagg N, Anderson RH, et al. Disposition of the atrioventricular conduction tissues in the heart with isomerism of the atrial appendages: Its relation to congenital complete heart block. J Am Coll Cardiol 1992; 20:904–910.
8. Wu MH, Lin JL, Wang JK, et al. Electrophysiologic properties of dual atrioventricular nodes in patients with right atrial isomerism. Br Heart J 1995; 74:553–555.
9. Saul JP, Walsh EP, Triedman JK. Mechanisms and therapy of complex arrhythmias in pediatric patients. J Cardiovasc Electrophysiol 1995; 6:1129–1148.
10. Wu MH, Wang JK, Lin JL, et al. Cardiac rhythm disturbance in patients with left atrial isomerism. PACE 2001; 24:1631–1638.

11. Hoffman TM, Bush DM, Wernovsky G, et al. Postoperative junctional ectopic tachycardia in children: Incidence, risk factors and treatment. Ann Thorac Surg 2002; 74:1607–1611.
12. Epstein MA, Saul JP, Weindling SN, et al. Atrioventricular reciprocating tachycardia involving twin atrioventricular nodes in patients with complex congenital heart disease. J Cardiovasc Electrophysiol 2001; 12:671–679.
13. Sarubbi B, Musto B, Ducceschi V, et al. Congenital junctional ectopic tachycardia in children and adolescents: 20 year experience based study. Heart 2002; 88:188–190.
14. Kanter RJ, Saba Z, Garson A Jr. Wide complex bigeminy: Unusual presentation of an atriofascicular fiber. J Cardiovasc Electrophysiol 1994; 5:795–802.
15. Guiraudon CM, Guiraudon GM, Klein GJ. Nodal ventricular Mahaim pathway: Histological evidence for an accessory atrioventricular pathway with AV node-like morphology (abstract). Circulation 1988; 78(Suppl II):II–40.
16. Kreiner G, Heinz G, Frey B, et al. Demonstration of retrograde conduction over an atriofascicular accessory pathway. J Cardiovasc Electrophysiol 1997; 8:74–79.
17. Okishige K, Goseki Y, Itoh A, et al. New electrophysiologic features and catheter ablation of atrioventricular and atriofascicular accessory pathways: Evidence of decremental conduction and the anatomic structure of the Mahaim pathway. J Cardiovasc Electrophysiol 1998; 9:22–23.
18. Lee KL, Chun HM, Liem LB, et al. Effect of adenosine and verapamil in catecholamine induced accelerated atrioventricular junctional rhythm: Insights into the underlying mechanism. PACE 1999; 22:866–870.
19. Bae EJ, Lee JY, Noh CI, et al. Sinus node dysfunction after Fontan modifications influence of surgical method. Int J Cardiol 2003; 88(2–3):285–291.
20. Wang JK, Lue HC, Wu MH, et al. Double-inlet ventricle in Chinese patients. Am J Cardiol 1993; 72(1):85–89.