

# Surgical Indications and Results of Mitral Valve Repair in Pediatric Patients With Ventricular Septal Defects Accompanied by Mitral Valve Regurgitation

Woo Sung Jang, MD, PhD, Woong-Han Kim, MD, PhD, Joon Yong Cho, MD, Kwangho Choi, MD, Eun Seok Choi, MD, Young Ok Lee, MD, PhD, Gun-Jik Kim, MD, Jeong Ryul Lee, MD, PhD, and Yong Jin Kim, MD, PhD

Department of Thoracic and Cardiovascular Surgery, Kyungpook National University Hospital, Kyungpook National University College of Medicine, Daegu; Department of Thoracic and Cardiovascular Surgery, Seoul National University Children's Hospital, Seoul; National University College of Medicine, Seoul; Department of Thoracic and Cardiovascular Surgery, Pusan National University Yangsan Children's Hospital, Pusan National University College of Medicine, Gyeongnam; and Department of Thoracic and Cardiovascular Surgery, Seoul National University Bundang Hospital, Seoul National University College of Medicine, Seoul, Republic of Korea

**Background.** Ventricular septal defects (VSDs) can be accompanied by mitral regurgitation (MR) owing to chronic volume overload or mitral valve (MV) abnormalities. This study investigates the surgical indications, results, and natural course of pediatric VSD patients with MR.

**Methods.** One hundred seven patients (median age, 4.5 months; median body weight, 6.2 kg; M:F = 46:61) who had VSD with accompanying MR between 2002 and 2012 were retrospectively analyzed and classified into two groups: group I, MV repair group; group II, no MV repair group.

**Results.** Of 107 patients, 48 patients (44.9%) required MV repair. Annular dilatation (n = 46) and anterior MV prolapse (n = 35) were the representative MV diseases in group I and their incidences were higher than in group II (n = 26 and n = 6, respectively; both  $p < 0.001$ ). Increased preoperative z values of MV annulus, and mean diastolic

and systolic left ventricle internal diameters were observed in group I ( $1.9 \pm 1.0$ ,  $3.4 \pm 1.3$ , and  $3.1 \pm 1.3$ , respectively) in comparison with group II ( $1.0 \pm 0.$ ,  $2.6 \pm 1.7$ , and  $2.3 \pm 1.7$ , respectively;  $p < 0.001$ ,  $p = 0.02$ , and  $p = 0.024$ , respectively). Posteromedial commissure annuloplasty in 23 patients and posterior annuloplasty in 19 patients were the most commonly used techniques to repair the MV; no reoperations were performed owing to MR. In group I, all patients showed an MR grade of 2 or less during the follow-up period. In group II, all patients showed the same or lower MR degree.

**Conclusions.** Mitral valve repair in pediatric VSD patients with accompanying MR is a feasible and durable procedure with growth potential.

(Ann Thorac Surg 2015;99:891–8)

© 2015 by The Society of Thoracic Surgeons

Ventricular septal defects (VSDs) are known to induce chronic left ventricular volume overload, which in turn increases the size of the left heart chamber, ultimately leading to the development of mitral regurgitation (MR) [1, 2]. Fortunately, however, a previous study has reported that this disease can be reversed after removal of the shunt burden and that patients may return to normal left ventricular volume 6 months after VSD closure [3]. In addition, Hisatomi and associates [4] reported that there was, in fact, no need for surgical mitral valve (MV) repair in a subset of VSD patients with MR who only exhibit annular dilatation but have normal MV morphology. Nonetheless, as structural MV abnormalities can sometimes accompany VSD, MV repair should be a potential consideration at the time of VSD repair. In pediatric

patients, however, although several MV repair techniques have been attempted, such as annuloplasty with prosthetic material and valvuloplasty with artificial chordae implantations [1, 2, 5], there have been clear limitations to its use as these prosthetic materials have no growth potential, thereby limiting their use.

Until now, the natural course of MR after VSD closure as well as the surgical indications and results of MV repair in pediatric patients with VSD have not been well studied. Therefore, the purpose of this study was to evaluate the natural course of MR after VSD closure and to assess the surgical indications and results of our MV repair technique in pediatric VSD patients with accompanying MR.

## Material and Methods

### Study Population

This study protocol was approved by our institutional review board, and all procedures were performed in

Accepted for publication Nov 12, 2014.

Address correspondence to Dr W-H Kim, Department of Thoracic and Cardiovascular Surgery, Seoul National University Children's Hospital, Seoul National University College of Medicine, 101 Daehak-ro, Jongno-gu, Seoul 110-744, Republic of Korea; e-mail: [woonghan@snu.ac.kr](mailto:woonghan@snu.ac.kr).

accordance with our institutional guidelines for the protection of patient confidentiality. The requirement for patient's consent was waived owing to the retrospective nature of this study.

Between February 2002 and December 2012, 1,898 patients presented with VSD in two hospitals. Among them, 107 patients (5.6%, 46 males and 61 females) who showed accompanying MR during the same period were included in this study. We divided the patients into two groups: Group I (VSD closure with MV repair group) (n = 48) and Group II (VSD closure without MV repair group; n = 59).

### Surgical Indications

Patients who had preoperative MR grades 3 or 4 with VSD underwent MV repair in all cases. In patients with MR grades 1 and 2, the decision to perform MV repair was made according to the degree of annular dilatation, MV prolapse, and other MV structural abnormalities by cardiac surgeons, cardiologists, and anesthesiologists. If the patients had more than a moderate degree of annular dilatation or definite MV prolapse, MV repair was performed.

### Surgical Techniques

An arterial cannula was inserted into the ascending aorta after median sternotomy, and standard bicaval cannulation was applied. During cooling, an aortic root cannula was inserted. A right atrial incision was performed after placing an aortic cross-clamp and beginning antegrade cold crystalloid cardioplegic solution infusion. Thereafter, MV repair after VSD closure was performed through the atrial septum in all patients. If the size of the atrial septal defect was small and thereby difficult to repair, the atrial septal incision was extended. In cases of annular dilatation with or without anterior MV prolapse, asymmetric annuloplasty to the posteromedial commissure was

performed using a method previously described by Kay and colleagues [6] and Reed and coworkers [7] with application of a 5-0 pledget-supported Ethibond coated braided polyester (Ethicon, Somerville, NJ) or posterior annulus plication with 6-0 pledget-supported Surgipro (US Surgical, Norwalk, CT) monofilament polypropylene sutures. In cases of asymmetric annuloplasty to the posteromedial commissure, we attempted to include more of the posterior leaflet area than the anterior leaflet area by means of suturing (Fig 1). When coaptation of the mitral leaflet after annuloplasty was not sufficient, additional annuloplasty or valvuloplasty was performed.

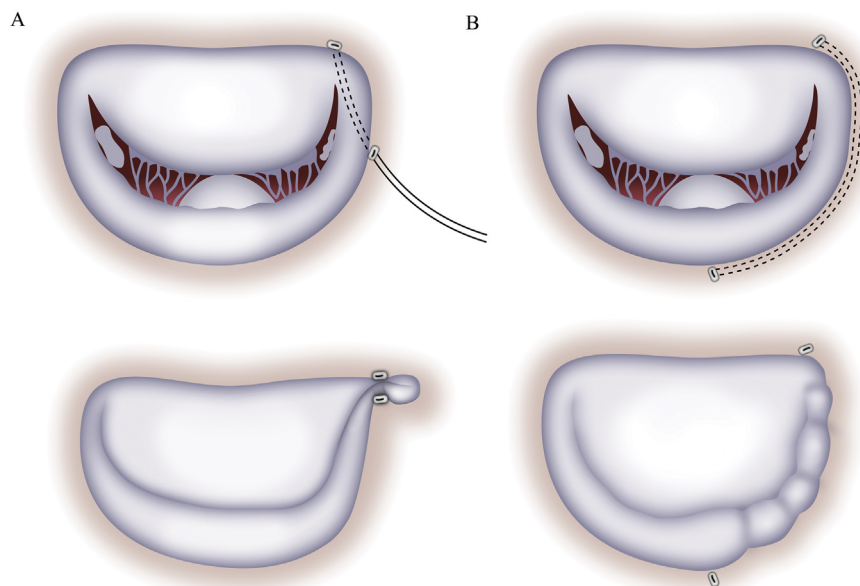
### Patient Follow-Up

Patients were monitored using echocardiography during the mean  $3.4 \pm 2.5$ -year follow-up period. Left ventricular function, ventricular volume, and the MR degree were evaluated. The MR degree was evaluated by means of a semiquantitative grading method according to the maximal length and width of the abnormal jet relative to the atrium using echocardiography: 0, no regurgitation or trivial regurgitation; 1, mild regurgitation; 2, moderate regurgitation; 3, moderate to severe regurgitation; 4, severe regurgitation [8]. The annulus size of the MV was measured in the parasternal long-axis view at the end-diastolic phase.

### Statistical Analysis

All continuous variables are expressed as mean  $\pm$  standard deviation or using median (25th to 75th percentiles) values, as appropriate. Categorical variables are expressed as frequencies and percentages. Comparisons between continuous variables were performed using Student's *t* test, and categorical variables were analyzed using Fisher's exact test. A log-rank test was used for comparisons between factors. A probability value of less

Fig 1. Representative mitral valve repair techniques. (A) Asymmetric annuloplasty to the posteromedial commissure. (B) Posterior annulus plication.



than 0.05 was considered to indicate a statistically significant difference. All analyses were performed using the SPSS statistical package (IBM SPSS version 19.0, SPSS Inc, Chicago, IL).

## Results

### Clinical Outcomes

The median age and body weight at surgery was 4.5 months (range, 2.3 to 9.2 months) and 6.4 kg (range, 4.8 to 8.1 kg), respectively. There were 72 patients with perimembranous type VSD, 22 patients with doubly committed juxtaarterial type VSD, 11 patients with muscular outlet type VSD, and 2 patients with total conal defect VSD.

Among the 107 pediatric VSD patients who presented with MR, 48 patients (44.9%, M:F = 20:28) required MV repair (group I): 7 patients with preoperative MR grade 1 (14.6%), 25 with preoperative MR grade 2 (52.1%), 10 with grade 3 (20.8%), and 6 patients with preoperative MR grade 4 (12.5%). Thirty-five patients with preoperative MR grade 1 (59.3%) and 24 patients with MR grade 2 (40.7%) did not require MV repair (group II;  $p < 0.001$ ; Fig 2). The representative MV disease in group I were annular dilatation (46 cases) and MV prolapse (35 cases; Table 1). All 41 cases of MV prolapse from both groups involved the anterior MV leaflets. The representative MV repair techniques used in this study were posteromedial commissure annuloplasty in 23 patients and posterior annuloplasty in 19 patients (Fig 3). Associated procedures included atrial septal defect closures in 68 patients, hypertrophied right ventricular muscle resections in 20 patients, patent ductus arteriosus divisions in 8 patients, tricuspid valvuloplasty in 6 patients, right ventricular outflow tract fibrotic endothelium resections in 4 patients, and aortic root reduction, pulmonary artery banding, and aortic valvotomy all in 1 patient. There were no early or late deaths related to the operations. Furthermore, there were no cases requiring reoperation owing to MR during the follow-up period. There were 4 surgery-related morbidities in 4 patients as follows: postoperative seizure in 1

patient, atrial flutter in 1, postoperative mediastinitis in 1, and postoperative bleeding in 1 patient. The mean follow-up duration was  $3.9 \pm 2.8$  years.

### Analysis According to Groups

The incidences of annular dilatation and MV prolapse were higher in group I ( $n = 46$  [95.8%] and  $n = 35$  [79.2%], respectively) than in group II ( $n = 26$  [44.1%],  $n = 6$  [10.2%], respectively; all  $p < 0.001$ ). Preoperative z values of MV annulus significantly increased in group I ( $1.9 \pm 1.0$ ,  $n = 34$ ) compared with those in group II ( $1.0 \pm 0.7$ ,  $n = 34$ ;  $p < 0.001$ ). Preoperative z values of the mean diastolic left ventricular internal diameter (LVIDd) and systolic left ventricular internal diameter (LVIDs) also increased in group I ( $3.4 \pm 1.3$ ,  $3.1 \pm 1.3$ , respectively) compared with those in group II ( $2.6 \pm 1.7$ ,  $2.3 \pm 1.7$ , respectively;  $p = 0.02$ ,  $p = 0.02$ , respectively). However, there was no difference in the ejection fraction (EF) between the two groups (group I:  $0.650 \pm 0.076$  versus group II:  $0.688 \pm 0.091$ ;  $p = 0.149$ ).

There were no significant differences in VSD type between the two groups ( $p = 0.668$ ). In addition, there was no difference in the preoperative pressure gradient across the VSDs between group I ( $35.5 \pm 22.2$  mm Hg) and group II ( $38.2 \pm 27.1$  mm Hg;  $p = 0.607$ ). The mean cardiopulmonary bypass time and aortic cross-clamp time ( $117.1 \pm 40.3$  minutes and  $77.0 \pm 28.5$  minutes, respectively) in group I were prolonged compared with those in group II ( $97.2 \pm 35.0$  minutes and  $57.1 \pm 22.2$  minutes, respectively;  $p = 0.008$ ,  $p < 0.001$ ; Table 1).

### Interval Changes of Mitral Regurgitation Grade With Time

GROUP I. All patients except one showed an MR grade of 2 or lower after MV repair at discharge. At the latest follow-up echocardiography, all patients showed the same or lower MR degree compared with their values at discharge during the mean  $3.7 \pm 2.2$ -year echocardiography follow-up period. There were 2 patients who showed mitral stenosis during follow-up for which they underwent posteromedial commissure annuloplasty. Their mean pressure gradient was 5 mm Hg in one patient 2.1 years after the operation and 4.1 mm Hg in the other patient 7.9 years after the operation.

GROUP II. All patients showed the same or lower MR degree without MV repair after the operation and showed the same or lower MR degree compared with values at discharge during the mean  $3.9 \pm 3.1$ -year follow-up period (Fig 4).

### Interval Changes of the Mitral Valve Annulus, Left Ventricle Internal Diameter, and Ejection Fraction With Time

In group I, the z value of the MV annulus ( $0.24 \pm 0.8$ ) was nearly normalized at the latest follow-up compared with the preoperative MV annulus z value ( $1.9 \pm 1.0$ ;  $n = 32$ ;  $p < 0.001$ ). The z values of LVIDd ( $0.7 \pm 1.5$ ;  $n = 41$ ) and LVIDs ( $1.5 \pm 1.5$ ;  $n = 41$ ) at discharge nearly normalized after the operation and decreased compared with the

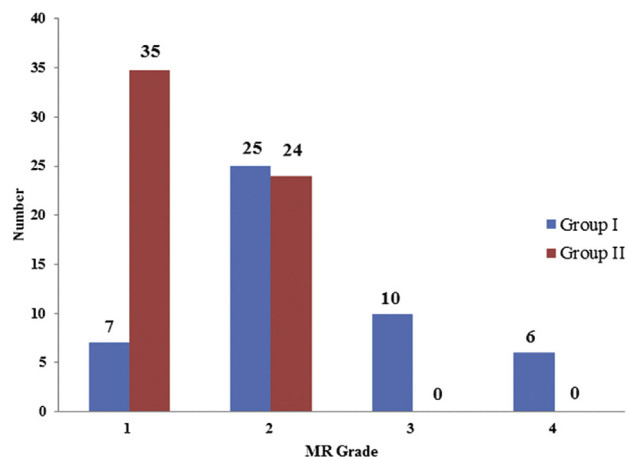


Fig 2. Preoperative mitral regurgitation (MR) grade in both groups.

Table 1. Clinical Characteristics of Patients in the Two Groups

MR Disease	Group I (48 Patients)	Group II (59 Patients)	p Value
Age, median (Q <sub>1-3</sub> ), mo (n)	4.6 (3.0-8.4) (48)	4.4 (2.2-9.8) (59)	0.150
Sex, M:F	20:28	26:33	0.803
Bwt, median (Q <sub>1-3</sub> ), kg (n)	6.7 (5.2-7.8) (48)	5.7 (4.5-8.6) (59)	0.590
Annular dilatation, n (%)	46 (95.8)	26 (44.1)	<0.001 <sup>a</sup>
MV prolapse, n (%)	35 (79.2)	6 (10.2)	<0.001 <sup>a</sup>
MV cleft, n (%)	1 (2.1)	0 (0%)	0.246
Shortened chordae, n (%)	1 (2.1)	0 (0%)	0.099
Pre MV annulus z score (n)	1.9 ± 1.0 (34)	1.0 ± 0.7 (34)	<0.001 <sup>a</sup>
Pre LVIDd z score (n)	3.4 ± 1.3 (32)	2.6 ± 1.7 (46)	0.016 <sup>a</sup>
Pre LVIDs z score (n)	3.1 ± 1.3 (31)	2.3 ± 1.7 (46)	0.020 <sup>a</sup>
Preop EF, (n)	0.650 ± 0.076 (20)	0.688 ± 0.091 (24)	0.149
VSD type, n (%)			0.668
PM	35 (72.9)	38 (64.4)	
DCJA	9 (18.8)	12 (20.3)	
MO	3 (6.3)	8 (13.6)	
Total conal defect	1 (2.1)	1 (1.7)	
PG across VSD (n)	35.5 ± 22.2 (40)	38.2 ± 27.1 (47)	0.607
CPB time, min (n)	117.1 ± 40.3 (48)	97.2 ± 35.0 (58)	0.008 <sup>a</sup>
ACC time, min (n)	77.0 ± 28.5 (48)	57.1 ± 22.2 (58)	<0.001 <sup>a</sup>

<sup>a</sup> p < 0.05.

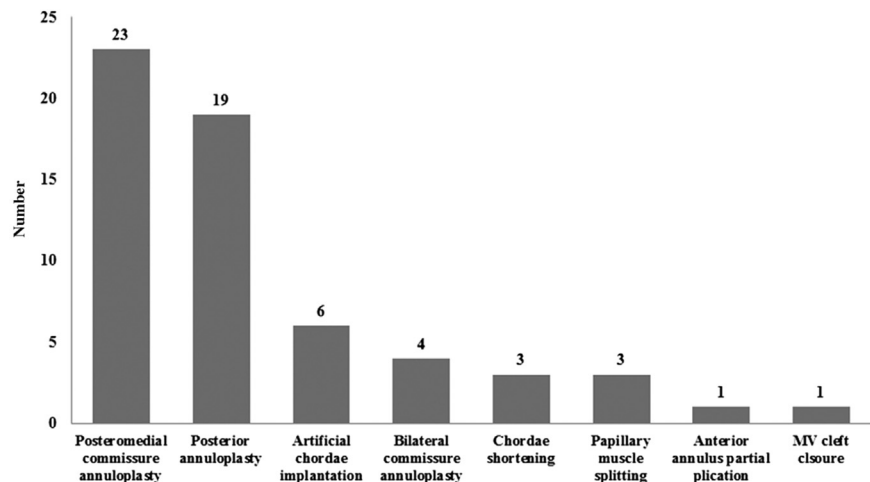
ACC = aorta cross clamp; Bwt = body weight; CPB = cardiopulmonary bypass; DCJA = doubly committed juxta-arterial type; EF = ejection fraction; LVIDd = diastolic left ventricle internal diameter; LVIDs = systolic left ventricle internal diameter; MO = muscular outlet; MV = mitral valve; PG = pressure gradient; PM = perimembranous; Q<sub>1-3</sub> = 25th-75th percentile intervals; VSD = ventricular septal defect.

preoperative values (all p < 0.001). The z values of LVIDd (0.2 ± 0.8; n = 41) and LVIDs (0.6 ± 1.1; n = 40) further improved at the latest follow-up compared with values at discharge at a mean follow-up period of 3.7 ± 2.1 years (p = 0.066, p = 0.005, respectively).

In group II, the z value of the MV annulus (0.46 ± 0.7) was also nearly normalized at the latest follow-up compared with the preoperative MV annulus z value (1.0 ± 0.7; n = 32; p = 0.003). In addition, the z values of LVIDd (0.7 ± 1.5; n = 54) and LVIDs (1.3 ± 1.5; n = 54) at

discharge were also nearly normalized and decreased compared with preoperative values (all p < 0.001). Furthermore, the z values of LVIDd (0.0 ± 1.0; n = 44) and LVIDs (0.3 ± 1.1; n = 44) also further improved at the latest follow-up compared with values at discharge at a mean follow-up period of 3.3 ± 2.8 years (p = 0.045, p = 0.004, respectively). Although the preoperative z values of the MV annulus, LVIDd, and LVIDs in group I were statistically higher than those of group II, there were no significant differences in MV annulus, LVIDd, and LVIDs

Fig 3. Mitral valve (MV) repair technique. Posteromedial commissure annuloplasty and posterior annuloplasty were the standard repair techniques.



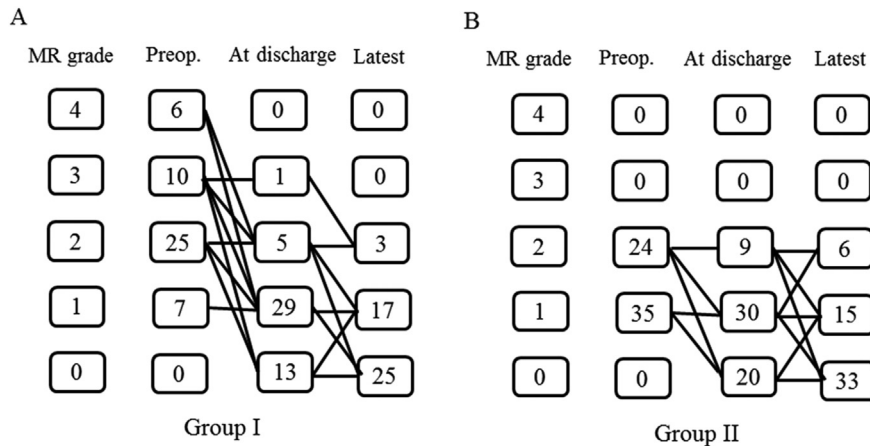


Fig 4. Mitral regurgitation (MR) grade changes over time. All patients showed an MR grade of 2 or lower after mitral valve repair at latest follow-up. In patients who did not undergo mitral valve repair, all patients showed the same or lower degree of MR at discharge, and maintained the same or lower degree of MR at the latest follow-up. (A) MR grade in group I. (B) MR grade in group II. (Preop = preoperative.)

at the latest follow-up between the two groups ( $p = 0.123$ ,  $p = 0.462$ , and  $p = 0.122$ , respectively).

In terms of the EF, both groups showed decreased values at discharge compared with the preoperative EF ( $0.600 \pm 0.088$ ;  $n = 28$ ;  $p = 0.007$  in group I;  $0.629 \pm 0.168$ ;  $n = 38$ ;  $p = 0.013$  in group II). However, EF was improved at the latest follow-up compared with that at discharge ( $0.651 \pm 0.062$ ;  $n = 37$ ;  $p = 0.005$  in group I;  $0.629 \pm 0.168$ ;  $n = 42$ ;  $p = 0.003$  in group II) and recovered to that at preoperative EF in both groups ( $p = 0.518$  in group I,  $p = 0.326$  in group II). There were no differences in EF between the two groups at the latest follow-up ( $p = 0.566$ ).

#### Subgroup Analysis of Mitral Regurgitation Grades 1 and 2

The incidences of annular dilatation, MV prolapse, and concomitant annular dilatation and MV prolapse were higher in group I than in group II for patients with MR grades 1 and 2 (all  $p < 0.05$ ). Among them, concomitant annular dilatation and MV prolapse in group I also showed a higher incidence than in group II in both MR grade 1 and 2 patients (all  $p < 0.05$ ; Table 2). The preoperative z value of MV annulus was higher in group I ( $2.1 \pm 0.8$ ;  $n = 23$ ) than in group II ( $1.0 \pm 0.7$ ;  $n = 34$ ) for patients with MR grades 1 and 2 ( $p < 0.001$ ). However, there were no significant differences in MV annulus z value at the latest follow-up between the two groups ( $0.4 \pm 0.8$  in group I;  $0.4 \pm 0.7$  in group II;  $p = 0.898$ ).

Among the 91 patients who showed preoperative MR grades 1 and 2 (group I = 32 patients, group II = 59 patients), all MR grade 2 patients in group I showed MR

grade improvement after MV repair at the latest follow-up. However, 6 patients (25.0%) in group II remained at MR grade 2 at the latest follow-up ( $p = 0.011$ ; Fig 5). Mean age at operation ( $5.5 \pm 4.1$  months;  $p = 0.580$ ), mean body weight ( $6.7 \pm 1.9$  kg;  $p = 0.185$ ), preoperative pressure gradient ( $25.3 \pm 32.1$  mm Hg;  $p = 0.983$ ), preoperative LVIDD z score ( $3.3 \pm 1.0$ ;  $p = 0.939$ ), preoperative LVIDs z score ( $2.9 \pm 1.1$ ;  $p = 0.679$ ), and preoperative EF ( $0.680 \pm 0.0057$ ;  $p = 0.331$ ) were assessed not to be risk factors of MR improvement in group II in this study. In addition, the incidence of annular dilatation ( $p = 0.478$ ), sex ( $p = 0.478$ ), and VSD type ( $p = 0.376$ ) did not correlate with MR grade improvement in group II according to univariate analysis. In cases of MR grade 1, 3 patients (3 of 7, 42.9%) in group I and 10 patients (10 of 35, 28.6%) in group II remained at the same MR grade at the latest follow-up ( $p = 0.652$ ).

#### Comment

In this study, we found that MV repair in pediatric VSD patients with MR was a feasible and procedure allowing appropriate growth potential for the MV. In addition, the preoperative dilated MV annulus and left ventricular volume was shown to be normalized after VSD closure at the latest follow-up. Furthermore, we also found that MV repair in patients with MR grade 2 showed a better likelihood of MR grade improvement than those without MV repair at the latest follow-up.

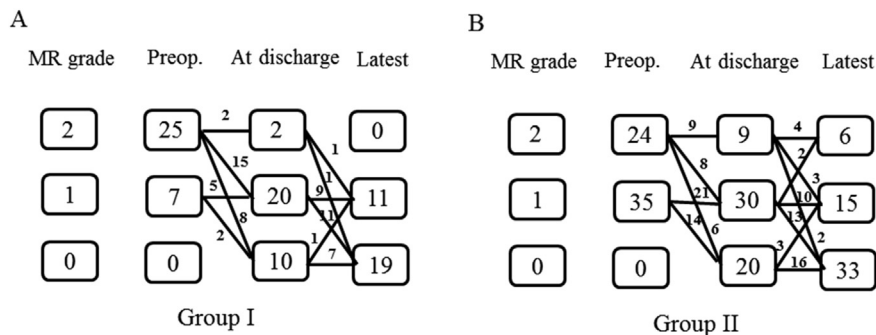
Mitral valve repair for the treatment of mitral insufficiency in pediatric patients is currently limited owing to

Table 2. Comparison of Mitral Valve Disease Between Patients With Mitral Regurgitation Grades 1 and 2

MV Disease	MR Grade 1			MR Grade 2		
	Group I (n = 7)	Group II (n = 35)	p Value	Group I (n = 25)	Group II (n = 24)	p Value
AD, n (%)	7 (100)	4 (11.4)	0.003	24 (96.0)	13 (54.2)	0.002
MVP, n (%)	4 (57.1)	6 (17.1)	0.043	23 (92.0)	0 (0)	<0.001
AD + MVP, n (%)	3 (42.9)	2 (5.7)	0.026	22 (88.0)	0 (0)	<0.001

AD = annular dilatation; MR = mitral regurgitation; MV = mitral valve; MVP = mitral valve prolapse.

Fig 5. Mitral regurgitation (MR) grade changes in patients with MR grades 1 and 2. All patients in group I with an MR grade of 2 showed MR grade improvement after mitral valve repair at the most recent follow-up. However, 6 patients (25.0%) in group II remained at MR grade 2 at the latest follow-up. (A) MR grade in group I. (B) MR grade in group II. (Preop = preoperative.)



the small size of the annulus and growth potential problems in children. Thus, a complete understanding of the function of the mitral annulus would be of great importance in determining which type of repair technique would be most appropriate. For the various surgical MV repair techniques available today, correction of the dilated annulus is a key procedure needed to achieve good and acceptable postoperative surgical results. Thus, we mainly applied posteromedial commissure annuloplasty and posterior annulus plication irrespective of the MV disease in pediatric VSD patients with MR in this study [6, 7, 9]. However, the main concern of our MV repair technique was its durability and the limitation of MV growth in children.

Annular dilatation is one of the major causes of MR in VSD patients [10], and prosthetic ring implantations have been considered the standard MV repair technique. According to a study by Carpentier and associates [11], who highlighted the importance of appropriate repair for individual lesions of the mitral apparatus, they were able to obtain good clinical results with the use of mitral rings for a variety of MV abnormalities. Chauvaud and colleagues [5] also reported the concept of successful annular remodeling with a prosthetic ring combined with leaflet enlargements in patients older than 2 years of age. However, controversy remains about the durability of the annuloplasty technique in pediatric patients as several reports of scar tissue caused by the sutures and the ring itself have been reported, potentially limiting proper annulus growth and leaflet motion [12]. Thus, successful MV repair techniques without the use of a prosthetic ring in pediatric patients have been introduced [13, 14]. Therefore, considering the median age of 4.5 months in this study, we opted not to insert a prosthetic ring.

Recently, Davachi and coworkers [10] reported that annular dilatation was the major cause of MR, that the leaflets themselves showed no important pathologic changes, and that it had good leaflet mobility. However, in our study, 41 cases (38.3%) of anterior MV prolapse were observed among 107 patients. Thus, MV prolapse may also be considered an important disease contributing to MR. To repair a prolapsed mitral leaflet in children, chordal augmentation using native chordae or artificial materials may be considered the first-line technique [5]. However, owing to the small size of the MV annulus

and the thin and fragile MV leaflets in our pediatric study, we performed annuloplasty, as originally reported by Kay and colleagues [6], and posterior annulus plication [5, 7, 9, 14]. As a result, all patients in group I showed an MR grade of 2 or lower after repair at the latest follow-up, demonstrating the effectiveness of our MV repair technique.

Another main concern was the growth potential problems after MV repair in pediatric patients. Hisatomi and associates [4] reported that in 4 of 11 patients who underwent bilateral annuloplasty, substantial mitral stenosis developed with a transmitral pressure gradient of more than 10 mm Hg on echocardiography in their latest follow-up. In our study, there were also 2 patients who showed mitral stenosis during follow-up for which they underwent posteromedial commissure annuloplasty. However, the mean pressure gradient of the MV was not severe and mild mitral stenosis was maintained. Thus, we found that growth problems after annulus plication in VSD patients with accompanying MR were not a concern in our study. Furthermore, we also performed bilateral commissure annuloplasty in 4 patients, and none of the 4 patients showed mitral stenosis during follow-up. Therefore, further evaluation may be required to determine the most effective technique in this regard.

At present, in VSD patients with MR, the surgical decision of whether or not to perform MV repair is not clear. This is because there have been only a few studies showing the surgical results after VSD closure in VSD patients with accompanying MR who did not undergo MV repairs [3, 4]. In addition, it may be difficult to determine whether MV repair is indeed appropriate in cases in which the MR degree is less than 2. In our study, we found that the incidence of annular dilatation, MV prolapse, and concomitant annular dilatation and MV prolapse were higher in group I than in group II, and that preoperative MV annulus z values were also higher in group I than in group II. Furthermore, in group I, all patients with MR grade 2 showed MR grade improvement in contrast to the 6 patients (25%) in group II who remained at the same MR degree at the latest follow-up. Thus, we suggest that if patients show a large annulus dilatation or definite MV prolapse with an MR grade of 2, MV repair may be considered, although we were not able to ascertain a specific cutoff value of MV annular

dilatation for MV repair in this study. However, in patients with MR grade 1, although the incidence of annular dilatation or MV prolapse was higher in group I than in group II, no difference in MR improvement after MV repair was observed. Therefore, in pediatric VSD patients with an MR grade of 1, observation rather than MV repair may be a better option if there is no definite MV prolapse or MV morphologic abnormality.

In conclusion, MV repairs including posteromedial commissure annuloplasty and posterior annulus plications in pediatric VSD patients with accompanying MR was demonstrated to be a feasible and durable procedure with appropriate growth potential for the MV after surgery. Furthermore, patients with grade 2 MR who underwent MV repair showed better MR grade improvement than patients without MV repair at the latest follow-up conducted for this study.

This study has several limitations. First, as this was a retrospective study, the surgical indications and strategies were not the same for the two centers involved in this study. In addition, quantification and measurement of the degrees of MV prolapse were unable to be obtained. Finally, we were not able to assess long-term outcomes in this study, and therefore future studies with longer follow-up periods are warranted.

## References

- Kleinman CS, Tabibian M, Starc TJ, Hsu DT, Gersony WM. Spontaneous regression of left ventricular dilation in children with restrictive ventricular septal defects. *J Pediatr* 2007;150:583–6.
- Papadimitriou JM, Hopkins BE, Taylor RR. Regression of left ventricular dilation and hypertrophy after removal of volume overload. Morphological and ultrastructural study. *Circ Res* 1974;35:127–35.
- Mahadin DR, Srivastava S, Parness IA, et al. Outcomes of mitral regurgitation associated with large ventricular septal defect and a normal mitral valve apparatus: does intact atrial septum have an impact? *Pediatr Cardiol* 2011;32:1128–31.
- Hisatomi K, Isomura T, Sato T, Kosuga K, Ohishi K, Katoh H. Mitral valve repair for mitral regurgitation with ventricular septal defect in children. *Ann Thorac Surg* 1996;62:1773–7.
- Chauvaud S, Fuzellier JF, Houel R, Berrebi A, Mihaileanu S, Carpentier A. Reconstructive surgery in congenital mitral valve insufficiency (Carpentier's techniques): long-term results. *J Thorac Cardiovasc Surg* 1998;115:84–93.
- Kay JH, Egerton WS, Zubiate P. The surgical treatment of mitral insufficiency and combined mitral stenosis and insufficiency with use of the heart-lung machine. *Surgery* 1961;50:67–74.
- Reed GE, Tice DA, Clauss RH. Asymmetric exaggerated mitral annuloplasty: Repair of mitral insufficiency with hemodynamic predictability. *J Thorac Cardiovasc Surg* 1965;49:752–61.
- Sheikh KH, Bengtson JR, Rankin JS, de Bruijn NP, Kisslo J. Intraoperative transesophageal Doppler color flow imaging used to guide patient selection and operative treatment of ischemic mitral regurgitation. *Circulation* 1991;84:594–604.
- Delmo Walter EM, Siniawski H, Ovroutski S, Hetzer R. Mitral valve growth after posterior annular stabilization with untreated autologous pericardial strip in children with mitral valve insufficiency. *Ann Thorac Surg* 2010;90:1577–85.
- Davachi F, Moller JH, Edwards JE. Diseases of the mitral valve in infancy. An anatomic analysis of 55 cases. *Circulation* 1971;43:565–79.
- Carpentier A, Chauvaud S, Fabiani JN, et al. Reconstructive surgery of mitral valve incompetence: ten-year appraisal. *J Thorac Cardiovasc Surg* 1980;79:338–48.
- Stellin G, Bortolotti U, Mazzucco A, et al. Repair of congenitally malformed mitral valve in children. *J Thorac Cardiovasc Surg* 1988;95:480–5.
- Stellin G, Padalino M, Milanese O, et al. Repair of congenital mitral valve dysplasia in infants and children: is it always possible? *Eur J Cardiothorac Surg* 2000;18:74–82.
- Uva MS, Galletti L, Gayet FL, et al. Surgery for congenital mitral valve disease in the first year of life. *J Thorac Cardiovasc Surg* 1995;109:164–76.

## INVITED COMMENTARY

Mitral regurgitation (MR) accompanying ventricular septal defect (VSD) is uncommon and when present is often presumed to be a result of the physiologic mechanisms of VSD, with left ventricular dilatation that is a consequence of intracardiac shunting. The common expectation is for MR to regress as the ventricle remodels after VSD closure. Indeed, several studies have observed that ventricular volume load and associated MR regress with time after VSD closure alone [1, 2], or even without VSD closure [3]. Indications to intervene for specific types of MR in this setting may lack clear definition.

Among 1,898 consecutive VSD closures, Jang and colleagues [4] found MR in 5.6% of patients, and mitral repairs were judged necessary in half of those with MR. Of the patients who underwent concomitant mitral repair, 35 of 48 patients had prolapse of the anterior mitral valve leaflet, and the remaining patients had annular dilatation alone. At follow-up, all the patients who had VSD closure alone had regression or stability of the degree of MR. Of

the patients who underwent repair, MR was also stable or improved, although 2 patients had mild to moderate mitral stenosis.

Jang and colleagues demonstrate that, at least in short- to mid-term follow-up, annular growth and sustained competence is achievable when posterior annuloplasty and commissuroplasty techniques are used to repair the mitral valve in infancy. Such repair in infancy is not without cost, however, as evidenced by the 2 patients who exhibited mitral stenosis after repair.

The history of surgical and catheter-based interventions for cardiac defects is rife with junctures at which we are challenged to separate what we can do from what we should do. It is established that MR from annular dilatation regresses after closure of the VSD and generally does not require valvuloplasty. The fate of MR from structural valve abnormalities in addition to annular enlargement is less clearly defined. Jang and colleagues describe anterior leaflet prolapse as a common structural