



MAIN TEXT OPEN ACCESS

Clinical Results for Cardiovascular Xenografts Treated With Novel Anticalcification Protocols

Hong-Gook Lim¹ | Chang Ha Lee² | Jae Hong Lim² | Eung Re Kim² | Yong Jin Kim^{1,2} ¹Department of Thoracic and Cardiovascular Surgery, Seoul National University Hospital, Seoul National University College of Medicine, Seoul, South Korea | ²Department of Thoracic and Cardiovascular Surgery, Sejong General Hospital, Bucheon, South Korea**Correspondence:** Yong Jin Kim (kyj@snu.ac.kr)**Received:** 20 January 2025 | **Revised:** 20 March 2025 | **Accepted:** 1 April 2025**Funding:** This study was supported by SNUH Lee Kun-hee Child Cancer & Rare Disease Project, Republic of Korea (Grant: 23C0220100).**Keywords:** anticalcification | bioengineering | biomaterials | decellularization | xenograft

ABSTRACT

Background: Glutaraldehyde (GA) generates cross-links between cardiovascular xenografts to obtain tissue stability and attenuate antigenicity. However, the long-term durability of GA-fixed cardiovascular xenografts treated with previous anticalcification strategies has remained a challenge because tissue phospholipids, free aldehyde groups of GA, and residual antigenicity contribute to calcification. This study aimed to assess the safety, efficacy, and clinical performance of a bovine pericardial scaffold treated with our novel anticalcification protocols (Periborn) in patients with cardiovascular diseases.

Methods: Bovine pericardia were decellularized with 0.25% sodium dodecyl sulfate, 0.5% Triton X-100, and treated with a space-filler with polyethylene glycol. These tissues were cross-linked with 0.5% GA in a 75% ethanol +5% octanol organic solvent and treated with glycine for detoxification to produce Periborn. Between July 2015 and April 2022, 451 Periborn patches were implanted in 352 cases for cardiovascular surgeries.

Results: The mean age at the time of surgery was 22.74 ± 20.09 years (13 days–89.5 years), follow-up duration was 4.25 ± 2.56 years (17 days–8.6 years), and no patch-related mortalities were observed. Five patients were reoperated owing to patch-related complications including decreased mobility, erosion, pseudoaneurysm, and calcification, and the overall probability of freedom from Periborn-related reoperation was $99.4\% \pm 0.4\%$ at 1 year, $98.6\% \pm 0.7\%$ at 5 years, and $95.4\% \pm 3.2\%$ at 9 years.

Conclusions: This retrospective study demonstrates the safety and efficacy of the tissue-engineered Periborn bovine pericardial scaffold for the surgical repair of various cardiovascular diseases. The excellent durability and hemodynamic performance of Periborn make our novel anti-calcification protocol attractive and may require long-term follow-up to confirm durability and further research.

1 | Introduction

Glutaraldehyde (GA) is employed to cross-link cardiovascular xenografts, enhancing tissue stability and diminishing antigenicity. Nevertheless, the long-term durability of GA-fixed cardiovascular xenografts has remained a challenge owing to calcification, which is caused by tissue phospholipids, unbound GA aldehyde groups, and residual antigens [1]. We have

developed a novel four-step anticalcification protocol, including decellularization [1], space filler [2], organic solvent [1, 3, 4], and detoxification [1, 3, 4].

Devitalized cells and cellular remnants can induce an immunological response against residual xenoantigens in a host, resulting in the formation of a nidus for calcification. We developed an optimal decellularization protocol using sodium dodecyl sulfate

This is an open access article under the terms of the [Creative Commons Attribution-NonCommercial-NoDerivs](https://creativecommons.org/licenses/by-nc-nd/4.0/) License, which permits use and distribution in any medium, provided the original work is properly cited, the use is non-commercial and no modifications or adaptations are made.

© 2025 The Author(s). *Artificial Organs* published by International Center for Artificial Organ and Transplantation (ICAOT) and Wiley Periodicals LLC.

(SDS) via a multi-step method with hypotonic, isotonic, and hypertonic buffer solutions [1]. We added a space filler to:

- Inactivate the free aldehyde groups of GA by reacting them with macromolecules.
- Form a barrier to prevent the release of residual GA.
- Exclude host-plasma calcium and phospholipids by filling inter-tropocollagen spaces.
- Block hydroxyapatite crystal nucleation sites.
- Mask platelet receptor sites on collagen to prevent platelet attachment and aggregation.
- Increase hydrophilicity with a subsequent reduction in protein adsorption and platelet adhesion [2, 5].

An organic solvent containing 75% ethanol and 5% octanol was used to reduce calcification by removing tissue phospholipids or inducing conformational changes in collagen and elastin [1, 3, 4]. The free aldehyde groups of GA exert detrimental cytotoxic effects. We employed a detoxification process in which glycine reacts with free aldehyde groups of GA to form a Schiff base [1, 3, 4].

The GA-fixed bovine pericardial scaffolds were treated with our unique anticalcification procedures to produce Periborn (Taewoong Medical Co., Gimpo, Korea), which features:

- Reduced immune response owing to the decellularization process [1].
- Prevented calcification by filling the interstitial void space [2, 5] and removing phospholipid [1, 3, 4].
- Reduced cytotoxicity owing to the detoxification process for reducing the residual free aldehyde [1, 3, 4].
- Improved strength and degradation resistance owing to glutaraldehyde-solvent cross-linking [1, 3, 4].
- Sterility owing to the aseptic processing techniques and liquid chemical sterilization.

This study aims to assess the safety, efficacy, and patch-related complications of Periborn in patients with cardiovascular disease.

2 | Materials and Methods

2.1 | Tissue Preparation and Treatment

Bovine pericardial tissues were washed with 0.9% normal saline, followed by 0.1% peracetic acid with 4% ethanol in distilled water for 1 h, and then further washed for 2 h with distilled water. These tissues were initially treated with a hypotonic buffered solution containing 0.25% SDS for 24 h at 4°C and washed with distilled water for 1 h. Then, they were treated with a hypotonic solution with 0.5% Triton X-100 for 24 h at 4°C and washed with distilled water for 12 h at 4°C. The tissues were then treated with an isotonic solution for 24 h at 4°C, followed by treatment with a

hypertonic buffered solution (II) for 6 h at 4°C and washed with phosphate-buffered solution (PBS) for 1 h at 4°C.

These tissues were treated with 25% polyethylene glycol (1000MW) in 0.01 M PBS (pH 7.4) for 1 day at 4°C.

2.2 | Fixation and Final Treatment

They were initially fixed with 0.5% GA for 3 days at room temperature, 0.25% GA in an organic solvent of 75% ethanol + 5% octanol for 2 days at room temperature, and finally with 0.25% GA for 7 days at room temperature. After fixation, the tissues were treated with 0.2 M glycine solution (PBS, pH 7.4) at 4°C for 24 h to produce Periborn. The tissues were sterilized with ethylene oxide before implantation in patients.

2.3 | Clinical Application, Patient Data Collection, and Ethical Considerations and Approval

According to the Ministry of Food and Drug Safety, GMP certificates were obtained on Aug 20, 2014, and marketing approval was obtained on May 6, 2015, to commercialize PERIBORN with Category No. B04020.01. The types of Periborn patches used included BP0108 (0.8 × 8 cm size, 0.35 ± 1.5 mm thickness), BP0209 (2 × 9 cm size, 0.35 ± 1.5 mm thickness), BP0404 (4 × 4 cm size, 0.35 ± 1.5 mm thickness), BP0506 (5 × 6 cm size, 0.35 ± 1.5 mm thickness), and BP0710 (7 × 10 cm size, 0.35 ± 1.5 mm thickness). Between July 2015 and April 2022, 451 Periborn patches were implanted in 352 cases for cardiovascular surgeries without exclusion criteria at Sejong General Hospital. Data on Periborn were retrospectively extracted from hospital medical records. This study was approved by the Institutional Review Board of Sejong General Hospital (IRB No: 24-05-007; Dated 2024. 5. 29). The requirement for patient consent was waived because of the retrospective nature of the study.

Table 1 provides details on the number and sites of implantation and type of the intervention for a total of 451 patches. Before surgery, 18 of 352 patients had infections, including endocarditis in seven patients and graft infection in one patient. Biological samples such as white blood cells (WBC), red blood cells (RBC), platelets, and C-reactive protein (CRP) were collected for laboratory testing to detect perioperative infections.

2.4 | Statistical Analysis

Statistical analyses were performed using the SPSS software (version 29.0; SPSS Inc., Chicago, IL, USA). All descriptive data were expressed as mean ± standard deviation, and a $p < 0.05$ was set as the level of statistical significance. Freedom from events, including reoperations, was determined using the Kaplan–Meier method. The variables were evaluated using the likelihood ratio test in the Cox proportional hazards regression model. Hazard ratios (HR) with 95% confidence intervals (CI) were calculated for the significant predictors. The follow-up status of the patients was determined through a retrospective review of hospital records or telephone interviews.

TABLE 1 | The site of implantation for 451 patches.

Site of implantation	No
Rt-sided heart reconstruction	270 (59.9%)
RVOT reconstruction	148
PA reconstruction	119
RA reconstruction	3
Septal defect reconstruction	105 (23.3%)
VSD repair	73
ASD repair	32
Lt-sided heart reconstruction	33 (7.3%)
LVOT reconstruction	32
Aortic root reconstruction	15
Aorta reconstruction	13
Subaortic area reconstruction	3
Aortic arch reconstruction	1
TAPVR repair	1
Vascular reconstruction	27 (6.0%)
Femoral artery reconstruction	17
Carotid artery reconstruction	4
Radial artery reconstruction	2
Brachial artery reconstruction	1
Iliac artery reconstruction	1
Popliteal artery reconstruction	1
Innominate vein reconstruction	1
Valve procedure	16 (3.6%)
TV repair	8
Aortic valve repair	4
MV repair	3
Atrioventricular valve repair	1

Abbreviations: ASD, atrial septal defect; LVOT, left ventricular outflow tract; MV, mitral valve; PA, pulmonary artery; RA, right atrium; RVOT, right ventricular outflow tract; TAPVR, total anomalous pulmonary venous return; TV, tricuspid valve; VSD, ventricular septal defect.

3 | Results

At the time of surgery, the patient characteristics were as follows:

- Age: 22.74 ± 20.09 years (median, 19.03; range 13 days–89.5 years).
- Pediatric cases ($n = 176$) versus adult cases ($n = 176$).
- Body weight: 46.97 ± 24.97 kg (median, 51 kg).
- Height: 143 ± 34.2 cm (median, 156.2 cm).
- Body surface area: 1.34 ± 0.52 m² (median, 1.5 m²).

After surgery, 26 of the 352 patients developed infections before discharge. The preoperative WBC count was 7.92 ± 3.34 K/uL (median, 7.22; range, 3.37–33.47 K/uL). The preoperative RBC count was 4.72 ± 0.68 m/uL (median, 4.75; range, 2.44–9.63 m/uL). The preoperative platelet count was 262.03 ± 93.79 K/uL (median, 242; range, 42–744 K/uL). The preoperative CRP level was 6.65 ± 23.12 mg/dL (median, 1.2; range, 0.4–214.3 mg/dL). The postoperative WBC count was 9.91 ± 4.14 K/uL (median, 9.2; range, 2.29–38.37 K/uL). The postoperative RBC count was 4.01 ± 0.71 m/uL (median, 3.99; range, 2.44–10.8 m/uL). The postoperative platelet count was 270.47 ± 108.16 K/uL (median, 254; range, 12.4–856 K/uL). The postoperative CRP level was 25.49 ± 33.5 mg/dL (median, 19.4; range, 0.5–382.9 mg/dL).

The mean follow-up duration was 4.25 ± 2.56 years (median, 4.45, 17 days–8.6 years). No patch-related mortalities were observed. The length of hospital stay was 12.84 ± 30.88 days (median, 8; range, 1–560 days). Postoperative echocardiography was performed in 334 patients at 7.76 ± 7.28 days (median, 5.5; 1–59) postoperatively. There were no abnormal findings, such as implant-related thromboembolism, infection, thickening, calcification, and hemodynamic compromise, in Periborn patches. Postoperative computed tomography (CT) was performed in 42 patients 7.79 ± 6.17 days (median, 6; 0–47) postoperatively. There were no abnormal findings.

The last echocardiography was performed in 289 patients at 4.7 ± 2.12 years (median, 4.65; range 0.09–8.57) postoperatively. No abnormal findings were observed. Last CT was performed in 115 patients 3.05 ± 2.27 years (median 2.9, 0.01–7.73) after operation. There was no abnormal findings.

TABLE 2 | Reoperations due to patch-related issues.

No	Age	Sex	Operation	Interval	Reoperation
1	10Y	M	AVP for rheumatic aortic steno-insufficiency	4Y	AVR
2	10Y	M	AVP for endocarditis with vegetations	14M	Ross procedure due to thickened pericardial tissue & decreased mobility
3	13Y	F	Aorta patch widening for small aorta with endocarditis	8Y	Redo AVR (Nicks procedure) and ascending aorta graft replacement
4	23Y	M	Aorta patch widening	4M	Repair of aortic pseudoaneurysm
5	77Y	M	Patch graft for infected Hemashield graft	9D	Closure for erosion at the patch site

Abbreviations: AVP, aortic valvuloplasty; AVR, aortic valve replacement.

Table 2 provides details on 5 reoperations due to patch-related issues. The overall probability of freedom from Periborn-related reoperation was:

- 99.4% ± 0.4% at 1 year.
- 98.6% ± 0.7% at 5 years.
- 95.4% ± 3.2% at 9 years (Figure 1).

Age, sex, perioperative infection, and follow-up duration did not affect the reoperation risk. Table 3 shows the univariate and multivariate associations between different predictors and Periborn-related reoperations. Cox proportional hazard model demonstrated that left ventricular outflow tract (LVOT) operation (HR, 7.433; 95% CI, 1.237–44.655; $p=0.028$), aorta repair (HR, 13.917; 95% CI, 2.301–84.161; $p=0.004$), valve repair of tricuspid valve (TV), aortic valve, mitral valve (MV), and atrioventricular valve (HR, 0.257; 95% CI, 0.105–0.629; $p=0.003$), and

aortic valve repair (HR, 0.110; 95% CI, 0.041–0.294; $p<0.001$) were significant risk factors in the univariate analysis, and aorta (HR, 39.116; 95% CI, 3.502–436.891; $p=0.003$) and aortic valve (HR, 215.616; 95% CI, 17.816–2609.393; $p<0.001$) repairs were significant risk factors in the multivariate analysis (Table 3).

4 | Discussion

In this study, our novel anticalcification protocols, including decellularization, space fillers, organic solvent, and detoxification, resulted in excellent clinical outcomes for our cardiovascular xenografts of Periborn. The large-animal long-term circulatory model has already demonstrated preclinical safety and efficacy in systemic valves [6, 7] as well as pulmonary valves [8–11] for our novel anticalcification protocols. However, the graft failures, as assessed by calcification and valvular function, were evident in the control groups [10, 12, 13]. These preclinical results provided the

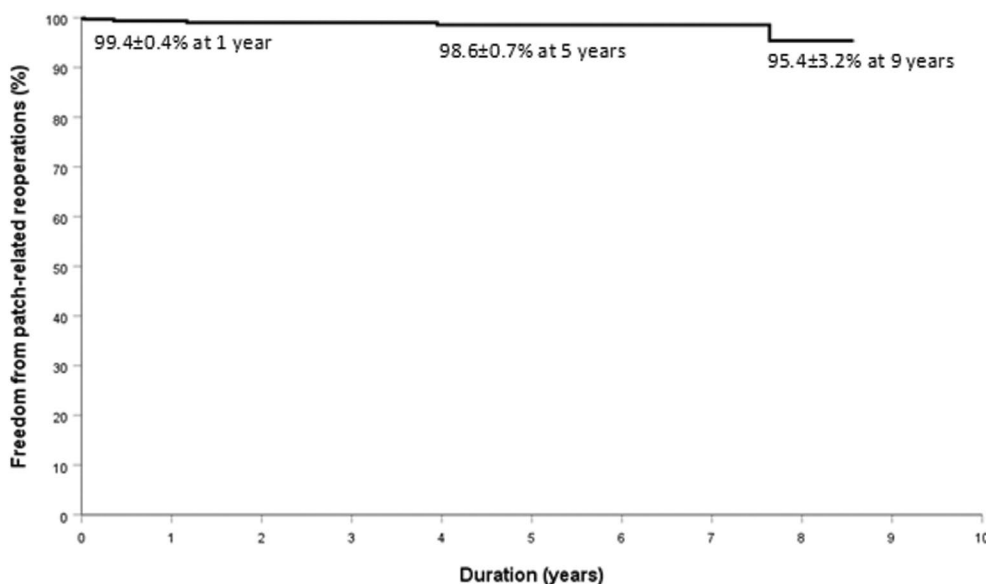


FIGURE 1 | Freedom from patch-related reoperations.

TABLE 3 | Risk factors for patch-related reoperations with Cox proportional hazard model.

Variable	Univariable			Multivariable		
	HR	95% CI	<i>p</i>	HR	95% CI	<i>p</i>
Age	1.010	0.968–1.054	0.641			
Sex	0.348	0.039–3.110	0.345			
Infection (pre)	0.158	0.017–1.440	0.102			
Infection (post)	0.168	0.017–1.643	0.125			
FU duration	0.747	0.450–1.242	0.261			
LVOT op	7.433	1.237–44.655	0.028			
Aorta repair	13.917	2.301–84.161	0.004	39.116	3.502–436.891	0.003
Valve repair	0.257	0.105–0.629	0.003			
AVP	0.110	0.041–0.294	<0.001	215.616	17.816–2609.393	<0.001

Note: The significance for bold values presented in Table 3 was $p<0.05$.

Abbreviations: AVP, aortic valvuloplasty; CI, confidence interval; FU, follow up; HR, hazard ratio; LVOT, left ventricular outflow tract; op, operation; Post, after operation; Pre, before operation.

foundation for the clinical application of our anticalcification protocols, where they were successfully implemented to the pulmonary valve of 692 patients, showing similar promising outcomes [14–17].

The first anticalcification protocol is complete decellularization, which reduces the immunogenicity of xenografts by removing cellular material [1, 18, 19]. We studied various decellularization methods to develop less immunogenic and exceptionally durable xenografts [20]. Considering the number and amount of chemicals used, incubation time, and degree of damage to the extracellular matrix, we concluded that a multistep method using a hypotonic solution followed by SDS was the optimal method for decellularization in our previous study [21]. To identify ideal conditions for decellularization, we explored modifications to the process parameters, including adjusting temperature and duration of treatment, altering osmotic pressure, and experimenting with different types and concentrations of chemical detergents [22]. As a high concentration of detergent causes significant matrix derangement, the use of a low detergent concentration and treatment with a hypertonic solution resulted in better mechanical characteristics [23]. After our decellularization, the removal of cellular components was verified and the success of the process was confirmed in hematoxylin and eosin staining, immunohistochemistry, and DNA content [1, 2, 5]. Our decellularization preserved the microscopic structure, degree of cross-linking assessed by thermal stability and pronase tests, degree of tissue strength assessed by uniaxial mechanical tests, and lowered the cytotoxicity [1, 5]. In vivo experiments with small animals proved that our decellularization protocol for xenografts reduced cytotoxicity, immune response, inflammation, and calcification and was effective [1, 5, 24]. Compared with other decellularization methods based on detergents and nuclease treatment [25, 26], our optimal decellularization protocol using SDS and Triton X-100 through a multistep method with hypotonic, isotonic, and hypertonic buffer solutions was developed without nuclease and successfully commercialized due to its economic feasibility and mass productivity [14–17].

The second anticalcification protocol uses a space filler to fill interstitial void spaces in GA-pretreated xenografts with a macromolecular substance that reacts with GA's free aldehyde groups to inactivate and mask platelet receptor sites [2, 5]. We demonstrated the effects of space-filler treatment on improving the properties of heart valve xenografts. In a rabbit subcutaneous or intramuscular implantation model, space-filler treatment effectively mitigated the in vivo calcification of GA-fixed xenografts for biological tissue preservation and reduced cytotoxicity in the GA-fixed xenografts [2, 5].

The third anticalcification protocol uses an organic solvent that reduces the calcification potential of aldehyde-fixed tissues by extracting phospholipids and inducing conformational changes in collagen [1, 3, 4]. Short-chain alcohols, such as ethanol, at high concentrations reduce the calcification potential of aldehyde-fixed tissues by removing phospholipids or inducing conformational changes in collagen. Alcohols preferentially bind to hydrophobic residues within collagen and elastin, which undergo independent calcification processes. The removal of phospholipids using a combination of short- and long-chain alcohols reduces the calcification potential of fixed tissues,

especially because long-chain alcohols are more structurally similar to phospholipids than short-chain alcohols and remove phospholipids more efficiently. Our anti-calcification treatment with solvents (77.5% ethanol and 2.5% octanol or 2.5% octandiol) did not worsen the physical properties while preventing in vivo calcification in a rat subdermal implantation model for 12 weeks compared to GA fixation alone [3]. We demonstrated that a 70% concentration of alcohols (65% ethanol and 5% octanol) did not alter the microscopic structure, amino acid composition, degree of cross-linking, and tissue strength. An in vivo calcification study of 70% alcohol (65% ethanol and 5% octanol) clearly demonstrated the excellent anti-calcification efficacy of this treatment [4]. We used 80% alcohol (a mixture of 75% ethanol and 5% octanol solution, 75% ethanol and 5% octandiol solution, and 70% ethanol and 10% isopropanol solution) instead of a pure organic solvent for the extraction of tissue phospholipids. These organic solvent treatments did not alter the microscopic structure, degree of crosslinking, and tissue strength [1]. The in vivo calcification study clearly demonstrated the excellent anticalcification efficacy of these organic solvent treatments, regardless of the organic solvent used [1].

The fourth anticalcification protocol is detoxification, which blocks the effects of free aldehyde groups of GA [1, 3, 4]. Amino acid post-fixation improves protein cross-linking to increase the mechanical performance of bioprostheses or neutralizes free aldehyde groups of GA, mitigating in vivo calcification. Our post-treatment with glycine did not alter the microscopic structure, the amino acid composition, degree of cross-linking, and tissue strength. An in vivo calcification test using a rat subcutaneous model for 8 weeks demonstrated almost complete inhibition of calcification, compared with conventional GA fixation without glycine treatment [4]. Our post-treatment with glycine, L-glutamic acid, and sodium bisulfite did not alter the microscopic structure, degree of cross-linking, and tissue strength [1]. In vivo calcification testing using a rabbit intramuscular model demonstrated inhibition of calcification in GA fixation with detoxification, compared with conventional fixation without detoxification, regardless of the reducing agent used [1].

In this study, there was no Periborn patch-related mortality, nor were there any abnormal findings, such as patch-related thromboembolism, infection, excessive thickening, calcification, or hemodynamic compromise in echocardiography and CT images. However, abnormal findings such as patch-related luminal narrowing, thrombosis, calcification, and aneurysmal degeneration, and patch-related mortality have been reported with other patches of CardioCel [27–29]. The Periborn patch crosslinked with 0.5% GA was more sterile than 0.05% in other patches, and infection of the patch crosslinked with low GA could not be excluded as a cause of death. Perioperative infection was assessed with blood counts and CRP levels, and not as a risk factor for reintervention in the Periborn patch. The synergistic efficacy of our four-step anti-calcification treatments may have contributed to their excellent clinical outcomes compared to other patches [27–29].

Age was not a risk factor for reintervention in this study; however, the risk of reintervention was reported to be greater in neonates and infants [29, 30]. We used 16 patches for valvuloplasty of the TV in eight cases, the aortic valve in four, the MV in three,

and the atrioventricular valve in one. Valve repair and aortic valve repair were risk factors for reintervention in univariate analysis, with aortic valve repair a risk factor in multivariate analysis. Periborn patches for valve repair ($n=12$), excluding aortic valve, were not related to reintervention. One patient with infective endocarditis and another with rheumatic aortic valve disease underwent aortic valve repair and required reintervention. Two patients without these conditions had aortic valve repair without subsequent reintervention. Reinterventions were related to rheumatic and infectious conditions rather than the patch itself, suggesting caution in patch selection under inflammatory conditions. Another study, although tested in a small sample, found that patch use for non-aortic valve repair was not predictive of higher reintervention rates. Patients undergoing aortic valve repair with a patch were seven times more likely to have reintervention compared to other sites [29, 31, 32].

In this study, LVOT and ascending aorta reconstruction were risk factors for reintervention in the univariate analysis, and only ascending aorta reconstruction was a risk factor in the multivariate analysis. Fifteen patches were applied for aortic root reconstruction without reintervention, and 13 were applied for the aorta with two reinterventions. One patient with infective endocarditis underwent aortic reconstruction and subsequently required a reintervention. The other patient developed a pseudoaneurysm complication due to exposure to systemic pressure after aortic reconstruction and subsequently required reintervention. Reinterventions were related to the condition of infection and high pressure or surgical technique, rather than the patch itself, suggesting that caution is required in patch selection and surgical anastomosis under conditions of inflammation and high pressure. Two of the seven patients required reintervention for the ascending aorta [30], although reconstruction of the aortic root and ascending aorta was not associated with an increased risk of reintervention [29]. We have no reintervention in one case of the aortic arch. There have been reports of 8% [29] and 50% [30] reintervention rates for aortic arch augmentation, although aortic arch repair did not generate a higher probability of reintervention [29].

Periborn provided durable repair without re-intervention when 105 patches for closure of the ventricular septal defect ($n=73$) and atrial septal defect ($n=32$) were implanted in the cardiac septal positions. The visceral surface of the patch may be better placed on the face of the lumen than on the parietal surface to reduce inflammatory reactions [33]. However, we could not conclusively demonstrate abnormal findings, such as patch-related thromboembolism, infection, excessive thickening, calcification, and hemodynamic compromise on both sides of the patches.

Reinterventions were required in the pulmonary artery (PA) of 7.7%, and the right ventricular outflow tract (RVOT) of 4% [27] and the use of a patch to augment the pulmonary arteries in neonates had a higher probability of re-intervention than that in older children [29]. However, there were no patch-related reinterventions in the PA and RVOT, and age was not a risk factor for reintervention in this study.

Although infective endocarditis [34, 35] and embolic neurological events [36] have been frequently reported in other studies,

we could not conclusively demonstrate infective endocarditis or embolic neurological events in any patient in this study.

5 | Conclusion

Cardiovascular xenografts with enhanced durability can reduce infection, reoperation, and mortality for cardiovascular patients. Compared with the existing treatments or scaffolds, the Periborn patch was superior in terms of patch-related complications for up to 8.6 years. By combining these four protocols, we have developed a comprehensive strategy that addresses both the immunogenicity and calcification potential of xenografts, leading to the improved clinical outcomes seen in this study. More long-term follow-up for improved biocompatibility without calcification, infection, and reoperation is needed in comparison with control groups. To improve long-term durability for cardiovascular xenografts, protocol refinement and removal of residual xenoantigens despite decellularization are needed in the future.

Author Contributions

All the authors were involved in the conceptualization and design of the study and the discussion of the results, and approved the final manuscript as submitted and agree to be accountable for all aspects of the work.

Conflicts of Interest

The authors declare no conflicts of interest.

References

1. H. G. Lim, S. H. Kim, S. Y. Choi, and Y. J. Kim, "Anticalcification Effects of Decellularization, Solvent, and Detoxification Treatment for Genipin and Glutaraldehyde Fixation of Bovine Pericardium," *European Journal of Cardio-Thoracic Surgery* 41, no. 2 (2012): 383–390.
2. S. Jeong, E. J. Yoon, H. G. Lim, S. C. Sung, and Y. J. Kim, "The Effect of Space Fillers in the Cross-Linking Processes of Bioprosthesis," *Bioresearch Open Access* 2 (2013): 98–106.
3. H. W. Chang, S. H. Kim, K. H. Kim, and Y. J. Kim, "Combined Anticalcification Treatment of Bovine Pericardium With Amino Compounds and Solvents," *Interactive Cardiovascular and Thoracic Surgery* 12 (2011): 903–907.
4. C. Lee, S. H. Kim, S. H. Choi, and Y. J. Kim, "High-Concentration Glutaraldehyde Fixation of Bovine Pericardium in Organic Solvent and Post-Fixation Glycine Treatment: In Vitro Material Assessment and In Vivo Anticalcification Effect," *European Journal of Cardio-Thoracic Surgery* 39 (2011): 381–387.
5. S. Park, S. H. Kim, H. G. Lim, C. Lim, and Y. J. Kim, "The Anti-Calcification Effect of Dithiobispropionimidate, Carbodiimide and Ultraviolet Irradiation Cross-Linking Compared to Glutaraldehyde in Rabbit Implantation Models," *Korean Journal of Thoracic and Cardiovascular Surgery* 46 (2013): 1–13.
6. H. G. Lim, G. B. Kim, S. Jeong, and Y. J. Kim, "Development of a Next-Generation Tissue Valve Using a Glutaraldehyde-Fixed Porcine Aortic Valve Treated With Decellularization, α -Galactosidase, Space Filler, Organic Solvent and Detoxification," *European Journal of Cardio-Thoracic Surgery* 48, no. 1 (2015): 104–113.
7. H. G. Lim, S. Jeong, G. B. Kim, W. Lee, K. H. Son, and Y. J. Kim, "Next-Generation Transcatheter Aortic Valve Implantation," *JTCVS Open* 3 (2020): 14–24.

8. H. G. Lim, G. B. Kim, S. Jeong, and Y. J. Kim, "Valved Conduit With Glutaraldehyde-Fixed Bovine Pericardium Treated by Anticalcification Protocol," *Korean Journal of Thoracic and Cardiovascular Surgery* 47 (2014): 333–343.
9. H. G. Lim, S. Jeong, J. S. Shin, C. G. Park, and Y. J. Kim, "Development of Novel Combined Anticalcification Protocols Including Immunologic Modification for Prolonged Durability of Cardiac Xenograft: Preclinical Study Using Large-Animal Long-Term Circulatory Models," *ASAIO Journal* 61 (2015): 87–95.
10. C. S. Park, Y. J. Kim, J. R. Lee, et al., "Anticalcification Effect of a Combination of Decellularization, Organic Solvents and Amino Acid Detoxification on Glutaraldehyde-Fixed Xenopericardial Heart Valves in a Large Animal Long-Term Circulatory Model," *Interactive Cardiovascular and Thoracic Surgery* 25, no. 3 (2017): 391–399, <https://doi.org/10.1093/icvts/ivx131>.
11. G. B. Kim, H. G. Lim, Y. J. Kim, E. Y. Choi, B. S. Kwon, and S. Jeong, "Novel Self-Expandable, Stent-Based Transcatheter Pulmonic Valve: A Preclinical Animal Study," *International Journal of Cardiology* 173, no. 1 (2014): 74–79.
12. C. Y. Kim, K. H. Kim, K. C. Moon, W. H. Kim, S. C. Sung, and Y. J. Kim, "Comparison of Different Methods of Aortic Valve Conduit Xenograft Preservation in an Animal Experiment Model; Fresh Cryopreservation Versus Acellularized Cryopreservation," *Korean Journal of Thoracic and Cardiovascular Surgery* 43 (2010): 11–19.
13. D. J. Kim, Y. J. Kim, W. H. Kim, and S. H. Kim, "Xenograft Failure of Pulmonary Valved Conduit Cross-Linked With Glutaraldehyde or Not Cross-Linked in a Pig to Goat Implantation Model," *Korean Journal of Thoracic and Cardiovascular Surgery* 45, no. 5 (2012): 287–294.
14. G. B. Kim, B. S. Kwon, and H. G. Lim, "First in Human Experience of a New Self-Expandable Percutaneous Pulmonary Valve Implantation Using Knitted Nitinol-Wire and Trileaflet Porcine Pericardial Valve in the Native Right Ventricular Outflow Tract," *Catheterization and Cardiovascular Interventions* 89, no. 5 (2017): 906–909.
15. G. B. Kim, M. K. Song, E. J. Bae, et al., "Successful Feasibility Human Trial of a New Self-Expandable Percutaneous Pulmonary Valve (Pulsta Valve) Implantation Using Knitted Nitinol Wire Backbone and Trileaflet α -Gal-Free Porcine Pericardial Valve in the Native Right Ventricular Outflow Tract," *Circulation. Cardiovascular Interventions* 11, no. 6 (2018): e006494.
16. S. Y. Lee, G. B. Kim, S. H. Kim, et al., "Mid-Term Outcomes of the Pulsta Transcatheter Pulmonary Valve for the Native Right Ventricular Outflow Tract," *Catheterization and Cardiovascular Interventions* 98, no. 5 (2021): E724–E732.
17. W. Y. Park, G. B. Kim, S. Y. Lee, et al., "The Adaptability of the Pulsta Valve to the Diverse Main Pulmonary Artery Shape of Native Right Ventricular Outflow Tract Disease," *Catheterization and Cardiovascular Interventions* 103, no. 4 (2024): 587–596, <https://doi.org/10.1002/ccd.30968>.
18. J. Nam, S. Y. Choi, S. C. Sung, et al., "Changes of the Structural and Biomechanical Properties of the Bovine Pericardium After the Removal of α -Gal Epitopes by Decellularization and α -Galactosidase Treatment," *Korean Journal of Thoracic and Cardiovascular Surgery* 45, no. 6 (2012): 380–389.
19. B. J. Min, Y. J. Kim, J. W. Choi, S. Y. Choi, S. H. Kim, and H. G. Lim, "Histologic Characteristics and Mechanical Properties of Bovine Pericardium Treated With Decellularization and α -Galactosidase: A Comparative Study," *Korean Journal of Thoracic and Cardiovascular Surgery* 45, no. 6 (2012): 368–379.
20. Y. W. Seong, Y. J. Kim, S. H. Kim, B. J. Min, Y. O. Lee, and H. G. Lim, "Effect of Trypsin on Physico-Dynamic and Histological Changes After Decellularization of Bovine Pericardium," *Korean Journal of Thoracic and Cardiovascular Surgery* 43 (2010): 565–575.
21. C. S. Park, Y. J. Kim, S. C. Sung, et al., "Study on an Effective Decellularization Technique for Cardiac Valve, Arterial Wall and Pericardium Xenographs: Optimization of Decellularization," *Korean Journal of Thoracic and Cardiovascular Surgery* 41 (2008): 550–562.
22. S. C. Sung, Y. J. Kim, S. Y. Choi, J. E. Park, K. H. Kim, and W. H. Kim, "A Study on an Effective Decellularization Technique for a Xenograft Cardiac Valve: The Effect of Osmotic Treatment With Hypotonic Solution," *Korean Journal of Thoracic and Cardiovascular Surgery* 41 (2008): 679–686.
23. W. S. Jang, Y. J. Kim, and S. H. Kim, "Effects on Tensile Strength and Elasticity After Treatment With Glutaraldehyde, Solvent, Decellularization and Detoxification in Fresh Bovine Pericardium," *Korean Journal of Thoracic and Cardiovascular Surgery* 43 (2010): 1–10.
24. H. G. Lim, S. Y. Choi, S. Jeong, J. S. Shin, C. G. Park, and Y. J. Kim, "In Vivo Efficacy for Novel Combined Anticalcification Treatment of Glutaraldehyde-Fixed Cardiac Xenograft Using Humanized Mice," *Journal of Biomaterials Applications* 29, no. 7 (2015): 929–940.
25. S. Rajabi-Zeleti, S. Jalili-Firoozinezhad, M. Azarnia, et al., "The Behavior of Cardiac Progenitor Cells on Macroporous Pericardium-Derived Scaffolds," *Biomaterials* 35, no. 3 (2014): 970–982.
26. S. Jalili-Firoozinezhad, S. Rajabi-Zeleti, A. Marsano, N. Aghdami, and H. Baharvand, "Influence of Decellularized Pericardium Matrix on the Behavior of Cardiac Progenitors," *Journal of Applied Polymer Science* 133 (2016): 43255.
27. D. Bell, K. Betts, R. Justo, et al., "Multicenter Experience With 500 cardioCel Implants Used for the Repair of Congenital Heart Defects," *Annals of Thoracic Surgery* 108 (2019): 1883–1888.
28. A. Tomšič, D. D. Bissessar, T. J. van Brakel, N. A. Marsan, R. J. M. Klautz, and M. Palmen, "Initial Experience and Early Results of Mitral Valve Repair With CardioCel Pericardial Patch," *Annals of Thoracic Surgery* 106 (2018): 1241–1244.
29. A. A. Patukale, S. P. Marathe, K. S. Betts, et al., "CardioCel for Repair of Congenital Heart Defects: Nationwide Results of Over 1000 Implants," *European Journal of Cardio-Thoracic Surgery* 64, no. 4 (2023): ezad343.
30. C. Pavy, G. Michiel on, J. L. Robertus, F. Lacour-Gayet, and O. Ghez, "Initial 2-Year Results of CardioCelVR Patch Implantation in Children," *Interactive Cardiovascular and Thoracic Surgery* 26 (2018): 448–453.
31. S. Nordmeyer, J. Kretzschmar, P. Murin, et al., "ADAPT-Treated Pericardium for Aortic Valve Reconstruction in Congenital Heart Disease: Histological Analysis of a Series of Human Explants," *European Journal of Cardio-Thoracic Surgery* 56 (2019): 1170–1177.
32. O. Deutsch, F. Bruehl, J. Cleuziou, et al., "Histological Examination of Explanted Tissue-Engineered Bovine Pericardium Following Heart Valve Repair," *Interactive Cardiovascular and Thoracic Surgery* 30 (2020): 64–73.
33. S. Prabhu, J. E. Armes, D. Bell, et al., "Histologic Evaluation of Explanted Tissue-Engineered Bovine Pericardium (CardioCel)," *Seminars in Thoracic and Cardiovascular Surgery* 29 (2017): 356–363.
34. L. M. Wiggins, B. Mimic, R. Issitt, et al., "The Utility of Aortic Valve Leaflet Reconstruction Techniques in Children and Young Adults," *Journal of Thoracic and Cardiovascular Surgery* 159 (2020): 2369–2378.
35. S. Nordmeyer, P. Murin, A. Schulz, et al., "Results of Aortic Valve Repair Using Decellularized Bovine Pericardium in Congenital Surgery," *European Journal of Cardio-Thoracic Surgery* 54, no. 6 (2018): 986–992, <https://doi.org/10.1093/ejcts/ezy181>.
36. S. C. Chivers, C. Pavy, R. Vaja, C. Quarto, O. Ghez, and P. E. F. Daubeney, "The Ozaki Procedure With CardioCel Patch for Children and Young Adults With Aortic Valve Disease: Preliminary Experience—A Word of Caution," *World Journal for Pediatric & Congenital Heart Surgery* 10 (2019): 724–730.